Radovan Hudák, David Kachlík
Ondřej Volný et al.

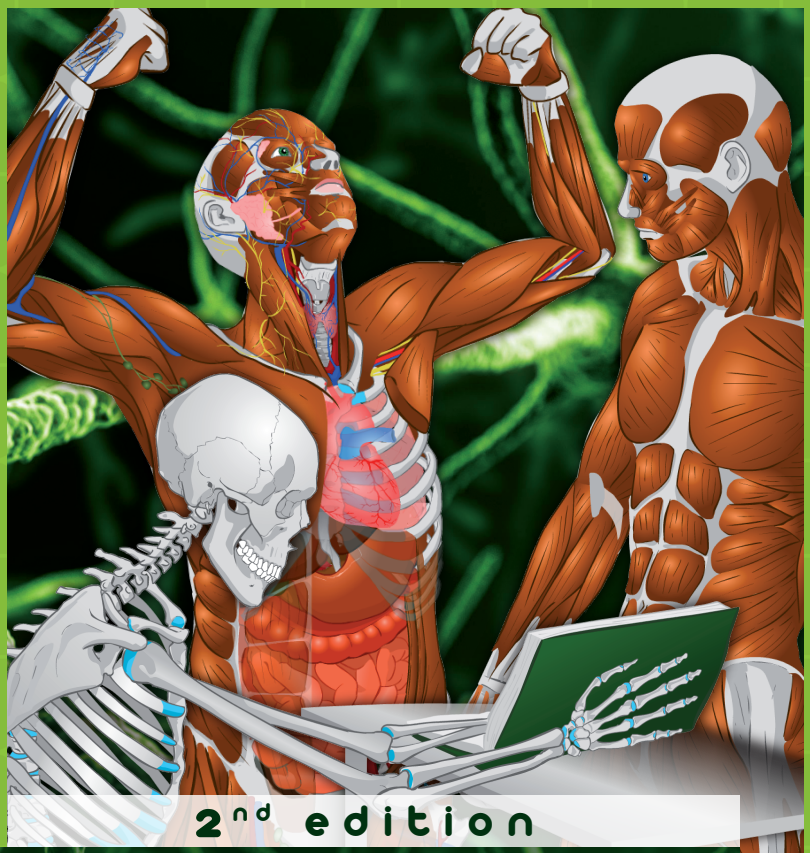

2nd edition

MEMORIX ANATOMY

Entire human anatomy in English and Latin

TRITON

Be an Anatomist at heart!

Book contents:

This sample contains a free chapter
1. General anatomy.
You will find it below the introduction of the book.
You can buy the whole ebook at our website.

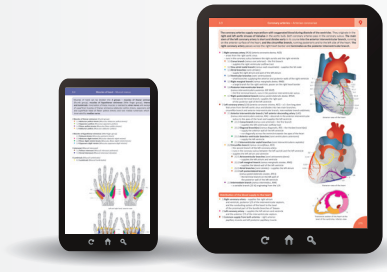





Review anatomy
anytime and anywhere

The Memorix Anatomy QUIZ app provides you with more than 15,000 flashcards, multiple-choice questions and figures to quickly test and revise your knowledge.

DOWNLOAD THE APP FOR FREE

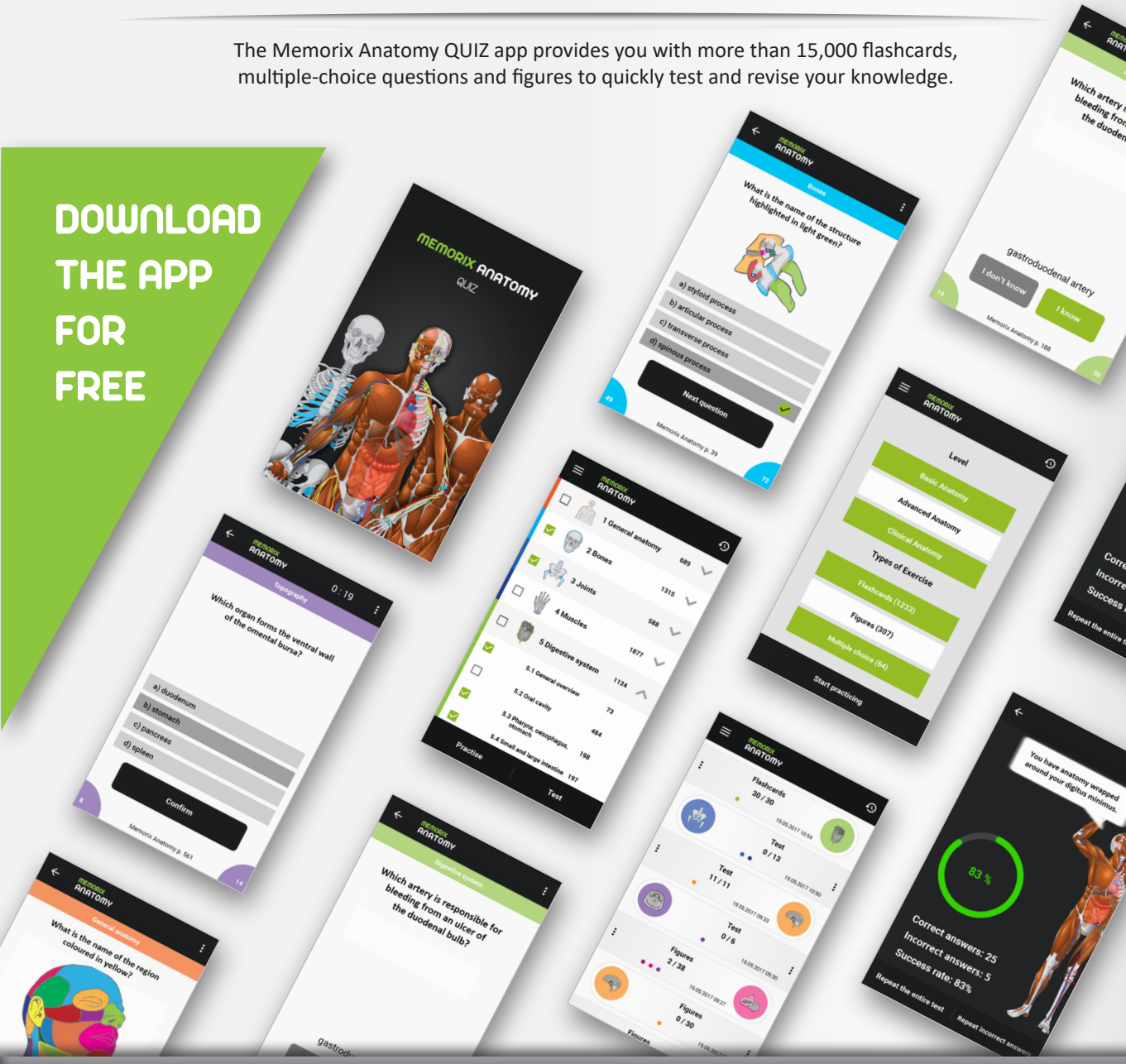

ANDROID APP ON Google play

Memorix Anatomy QUIZ

Mobile appliaction

Available on the App Store

Anatomical terms

in a free online dictionary

All anatomical terms in one place. Compare terms in different languages, ordered alphabetically or by systems.

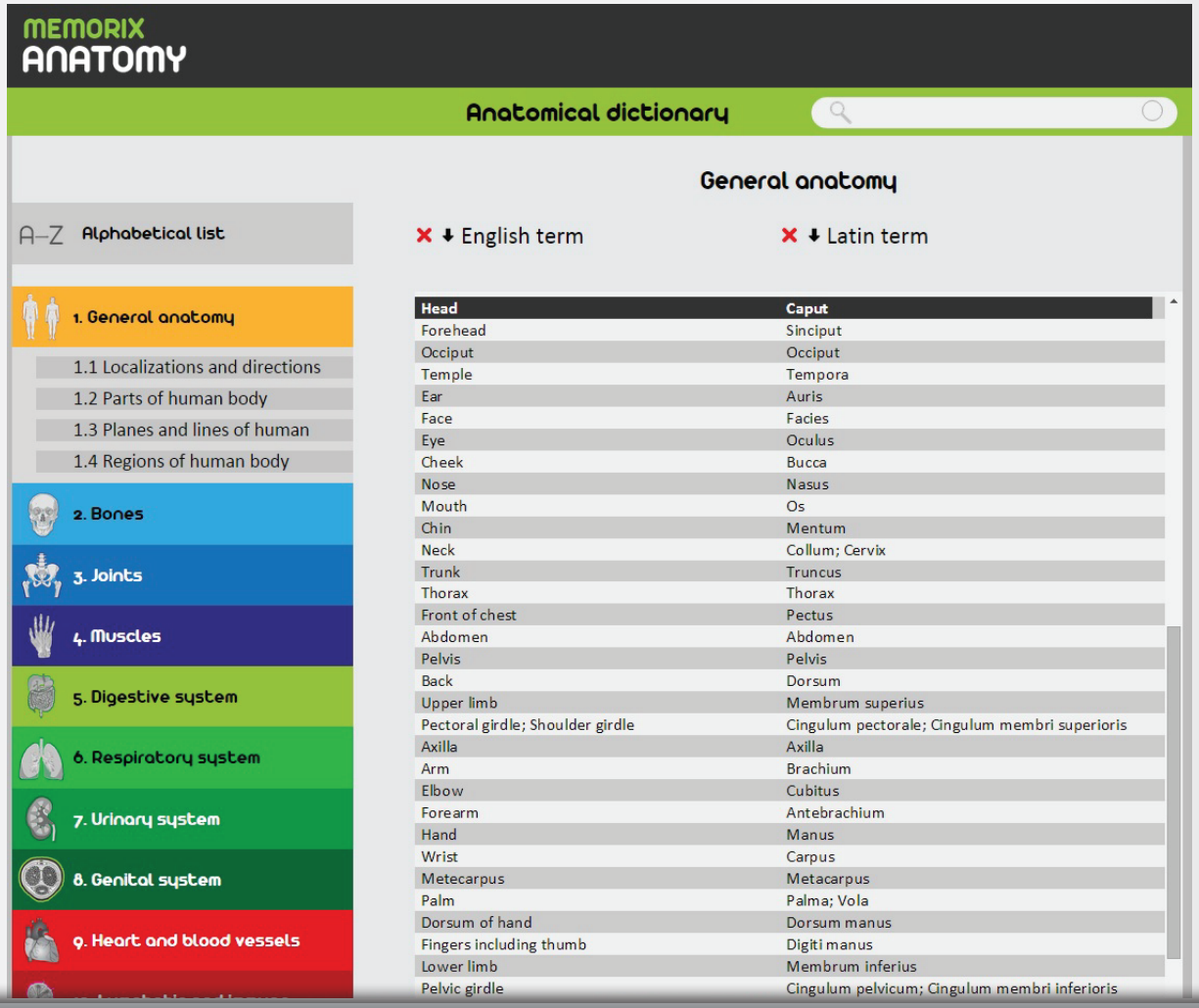

Head	Caput
Forehead	Sinciput
Occiput	Occiput
Temple	Tempora
Ear	Auris
Face	Facies
Eye	Oculus
Cheek	Bucca
Nose	Nasus
Mouth	Os
Chin	Mentum
Neck	Collum; Cervix
Trunk	Truncus
Thorax	Thorax
Front of chest	Pectus
Abdomen	Abdomen
Pelvis	Pelvis
Back	Dorsum
Upper limb	Membrum superius
Pectoral girdle; Shoulder girdle	Cingulum pectorale; Cingulum membri superioris
Axilla	Axilla
Arm	Brachium
Elbow	Cubitus
Forearm	Antebrachium
Hand	Manus
Wrist	Carpus
Metecarpus	Metacarpus
Palm	Palma; Vola
Dorsum of hand	Dorsum manus
Fingers including thumb	Digiti manus
Lower limb	Membrum inferius
Pelvic girdle	Cingulum pelvicum; Cingulum membri inferioris

Explore anatomical dictionary at

www.AnatomicalTerm.com

Practice Anatomy .com

and reinforce your knowledge

Practice medical anatomy with personalised questions.
Buy a subscription to access advanced questions and settings.
Use the code ILOVEMEMORIXANATOMY2017 to activate your 50% discount now!

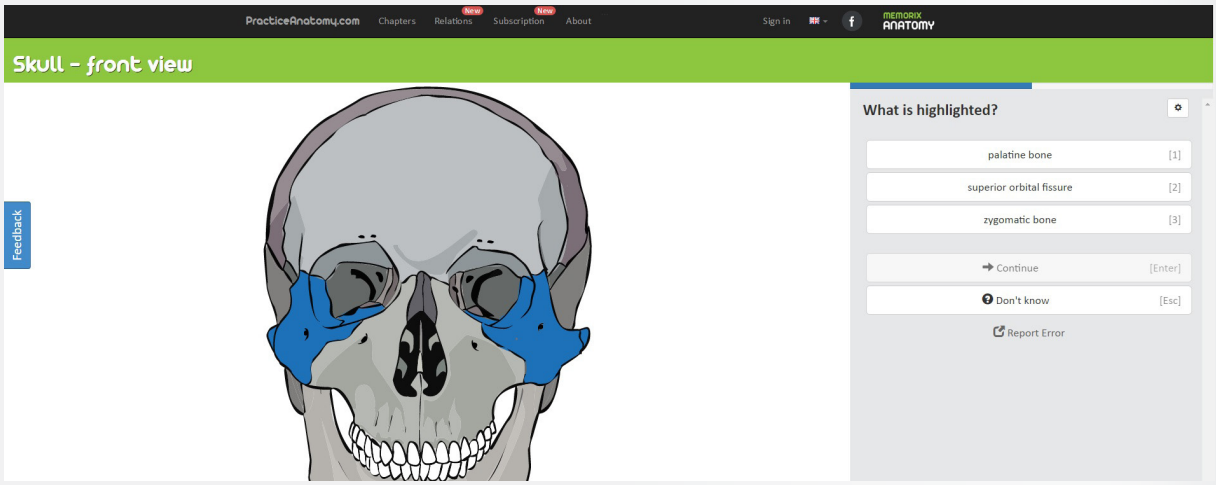

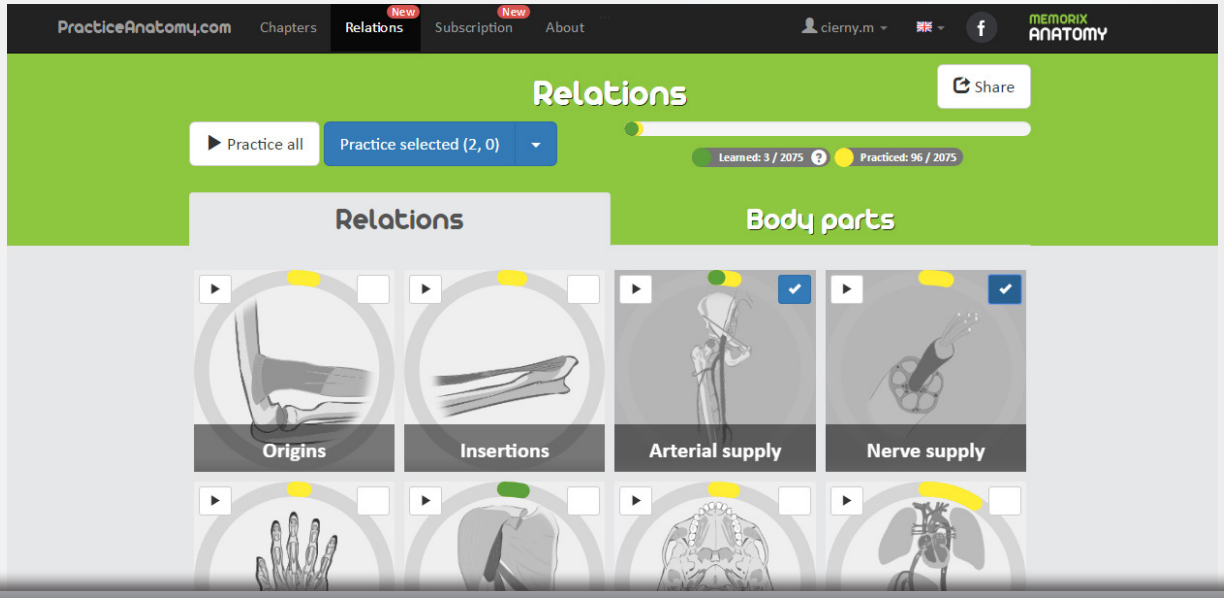

Test yourself at

www.PracticeAnatomy.com

Memorix Histology

Editors: **Jan Balko, Zbyněk Tonar, Ivan Varga et. al**

Managing editor: **Radovan Hudák**

We are pleased to announce the latest edition to Memorix series of textbooks: **Memorix Histology**. This groundbreaking textbook was created by the hard work and **cooperation of histologists, anatomists, pathologists, students and clinical doctors** and presents histological knowledge in an understandable and user-friendly way.

The concise text and emphasis on the most important information from cytology, histology and microscopic anatomy is combined with a simple design and **copious colour pictures and micrographs**. New to this edition are **algorithms for recognising micrographs** of various selected tissues.

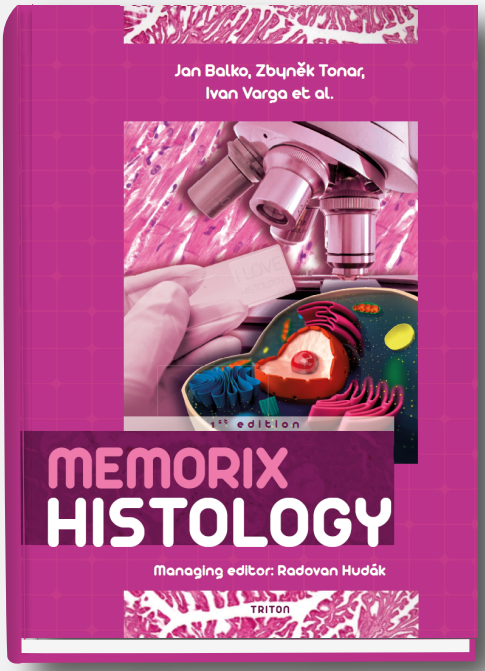

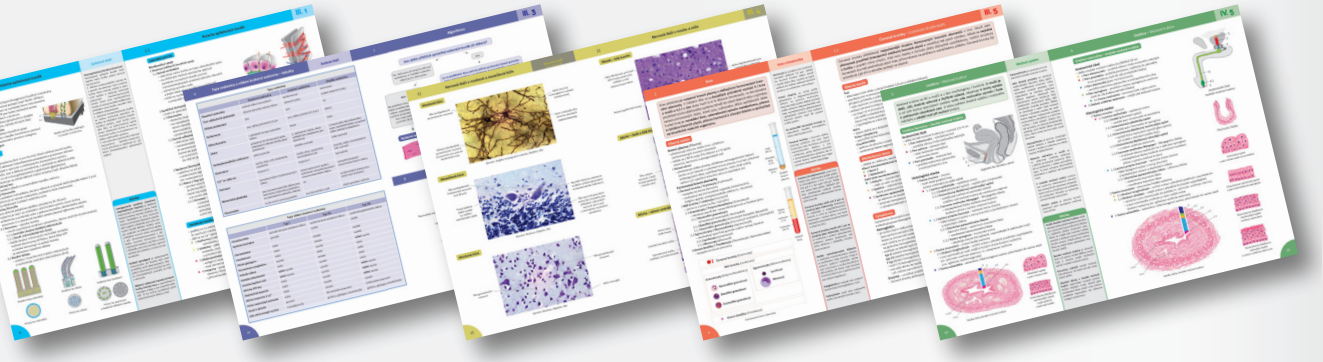

DOWNLOAD PREVIEW AND BUY AT

www.MemorixHistology.com

Dedicated to everyone who is an anatomist at heart.
Furthermore, to those who are not afraid
to make their dreams come true.

Radovan Hudák
David Kachlík
Ondřej Volný
et al.

MEMORIX ANATOMY

Entire human anatomy in English and Latin

2nd edition

MEMORIX

Radovan Hudák, David Kachlík, Ondřej Volný
MEMORIX ANATOMY

Copyright owner and publisher of the E-book:
MEMORIX s.r.o.,
Plzeňská 1270/97, 150 00 Praha 5, Czech Republic
www.memorixanatomy.com
1st edition published: 2015
2nd edition published: 2017
Last edit of the E-book: 1. 6. 2020

Illustrations: Jan Balko, Šárka Zavázalová, Radovan Hudák
Typesetting: Radovan Hudák, Matej Halaj, Vojtěch Kunc
Chiefs of copy editing and proofreading: Petr Vaněk, Adam Whitley
Copy editing and proofreading: Zuzana Balážová, Pavel Filip, Michal Vilímovský
Design: Radovan Hudák, Karel Novotný
Cover: Jan Balko, Karel Novotný, Radovan Hudák, Renata Brtnická

Publisher of the print book:
Stanislav Juhaňák – TRITON,
Vykáňská 5, 100 00 Praha 10
www.tridistri.cz

ISBN 978-80-906331-1-7

Memorix team

Editors

Radovan Hudák, MD
Assistant Professor, Department of Anatomy,
Second Faculty of Medicine, Charles University, Prague, Czech Republic

David Kachlík, MD, PhD
Professor, Department of Anatomy,
Second Faculty of Medicine, Charles University, Prague, Czech Republic

Ondřej Volný, MD, PhD
Assistant Professor, First Department of Neurology
St. Anne' Faculty Hospital and Faculty of Medicine, Masaryk University, Brno, Czech Republic

Co-authors

Barbora Beňová, MD
PhD student, Department of Paediatric Neurology,
Second Faculty of Medicine, Charles University and Motol University Hospital, Prague, Czech Republic

Martin Čepelík, MD
Clinician and Assistant Professor, Department of Pediatric Trauma and Surgery,
Third Faculty of Medicine, Charles University and Thomayer Hospital, Prague, Czech Republic

Ladislav Douda, MD
Clinician, 2nd Department of Internal Medicine – Gastroenterology,
Faculty of Medicine in Hradec Kralove, Charles University and University Hospital Hradec Kralove, Czech Republic

Matej Halaj, MD
Clinician, Department of Neurosurgery,
Faculty of Medicine and University Hospital, Olomouc, Czech Republic

Vojtěch Kunc
Student,
Second Faculty of Medicine, Charles University, Prague, Czech Republic

Jakub Miletín, MD
Clinician, Department of Plastic Surgery,
Assistant Professor, Department of Anatomy
Third Faculty of Medicine and University Hospital Královské Vinohrady, Prague, Czech Republic

Petr Vaněk, MD
Clinician, Department of Radiology
University Hospital Brno, Brno, Czech Republic

Adam Whitley, MD
Clinician, Department of General Surgery,
Third Faculty of Medicine and University Hospital Královské Vinohrady, Prague, Czech Republic
Assistant Professor, Department of Anatomy
Second Faculty of Medicine, Charles University, Prague, Czech Republic

Illustrators

Jan Balko, MD
Clinician, Department of Patology and Molecular Medicine,
Second Faculty of Medicine, Charles University and Motol University Hospital, Prague, Czech Republic

Šárka Zavázalová, MD
Clinician, Department of Otorhinolaryngology,
Third Faculty of Medicine, Charles University and Central Military Hospital, Prague, Czech Republic

Contents

4 Muscles 97

5 Digestive system 169

6 Respiratory system 205

7 Urinary system 225

8 Genital system 237

9 Heart and blood vessels 263

10 Lymphatic and immune systems 317

11 Peripheral nervous system 335

12 Central nervous system 389

13 Senses and skin 501

14 Endocrine system 521

15 Topography 529

„**Anatomy**, albeit it is feminine, **has its own charm and logic,**“ said one professor of anatomy a long time ago. Although **anatomy is as old as humanity itself, its charm is immortal and its logic still maintained**. Owing to these characteristics, anatomy belongs among favorite subjects, which students look forward to learning long before starting their university studies. However, **a great deal of specialized terms and information takes often smiles off students' faces** during their first week of school. Students usually don't give up and become devoted to studying, but the more they learn, the more they forget. They learn joints, but forget bones. When they manage to know the digestive system by heart, they in turn push out the muscles of the whole body. Forgetting things once learned brings them feelings of hopelessness and doubt whether they have what it takes to study medicine at all. The problem, though, is often not the amount of information, but rather their **way of learning and reviewing**. There are **many thousand-page anatomy textbooks** on the market comprising the immensity of anatomy, but there is just **a few of those that would provide information in a concise, clear, and understandable form**. And that is why **Memorix Anatomy** was created.

Dissatisfaction as a reason for change

Even most of us (the authors of this book) had to study anatomy for the first time and pass our first year of medical school just a few years ago. Just like the vast majority of medical students, we too wished to own a big book of anatomy of our own. We wanted to take pride in its complexity, size, and infinity in front of every person we knew. We felt so proud that we were medical students that we bought **three volumes of an anatomy textbook from one author, several other books by other authors, with two more color atlases** on top of that. We had more books from one field than from any other subject altogether and a **beautiful (but naive) idea we would once know it all**. **Do you recognize that feeling?** The excitement that you will be able to know in detail the origins and insertions of 300 muscles, the passages of the fourteen branches of the maxillary artery, or all the nuclei, tracts, and circuits in the brain? **An amazing image!** Amazing until you realize what we all know, but are unwilling to admit: **the fact that our memory has a limited capacity and chooses only the information our brain evaluates as important**. However, this is often not necessarily the information that is truly important.

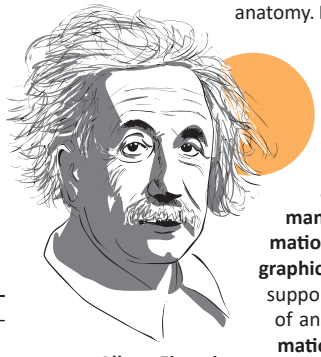

Albert Einstein

There was relatively enough time for studying at the beginning and we devoured important information along with the less important. As the final exam was approaching, so was the schoolwork volume exponentially growing, and the time was growing less and less. It became **necessary to distinguish the importance of information, adjust one's system, and study effectively**. Our large textbooks didn't suit us anymore and we were looking for something more clear and concise. **We were seeking tables, schemes, structured text, and simple images.** But we just could not find a book that would meet our needs.

One of the editors of this book, **Radovan Hudák**, had thought already during his study of medicine that he could **initiate the creation of such book as a student**. He contacted an **experienced anatomist, associate professor David Kachlík, M.D.**, with a question whether he wanted to collaborate on the **creation of a comprehensive, yet easy-to-understand anatomy book**. He thought it over and agreed. This initiated the creation of **Memorix Anatomie** (the Czech forerunner of this book), which was **in the spirit of Albert Einstein's** "**Everything should be made as simple as possible – but not simpler.**"

The base of success lies in cooperation

Before we started to build a team of authors, we asked ourselves a question, **„Who is this textbook intended for? For students, anatomists, or perhaps clinicians?“** We came to the conclusion that it was for all. Where a quality textbook should arise, it was necessary to have **a collaboration not only with anatomists who would guarantee quality anatomical content of the book, students who would ensure its comprehensibility, but also physicians who would add clinically important information**. Thus, more than half of the team of authors has been formed by **students who have already spent several years teaching anatomy to younger students from the position of student tutors**. The second part of the team consisted of **anatomists and clinicians**, who also significantly engaged themselves in anatomy. Even our **three illustrators have come from medical school**, so they knew very well what kind of pictures are best understood by students. The work of the Memorix team was also contributed to by **a large number of reviews by dozens of other anatomists, students, and physicians**.

The creation of this book cost us thousands of hours of hard work, but after 1.5 years we managed to finish it and get it to the students. **On a mere 600 pages, we have managed to summarize the most important anatomical information, which we have supplemented with more than 1,500 graphically uniform pictures.** The text and images are mutually supportive in order to significantly accelerate the understanding of anatomical structures. **Less important and interesting information were, together with clinical notes, set aside the main content** and placed in the middle column of each double page.

The sorting of the chapters, structured text, and large number of pictures has made **Memorix Anatomie a clear, systematic, and concise textbook designed for the effective learning and rapid reviewing of anatomy**.

After the success in the Czech and Slovak Republic, one of the co-authors of the Czech version, **Ondřej Volný**, couldn't resist and immediately initiated **the creation of an English version**. Again, the work involved a large number of **students, anatomists, and clinicians, only this time, from around the world**. Apart from the aforementioned features of the book, the Memorix book will be helpful to many students by having **all the structures described with English and Latin terms** right next to each other.

With the Memorix Anatomy book, we want to contribute to a **better understanding of anatomy among students**. We don't want them to see learning anatomy as necessary evil, but actually the other way around – to learn it with affection. **We would also like to motivate all students not to be afraid to address teachers with their ideas for improving teaching.** They will certainly appreciate it. And if not, contact us (*anatomy@memorix.cz*), because we will gladly hear out your thoughts and opinions. Who knows, we may create another useful study material together.

On behalf of the Memorix team
Radovan Hudák, David Kachlík, Ondřej Volný
Prague, Czech Republic, July 1, 2017

Anatomy can be learned very quickly. But it can also be quickly forgotten. To keep the anatomical knowledge in your memory, **it is necessary to study and repeat systematically**. That is why we created the **Memorix Education System** with **specialists in teaching psychology and andragogy** (teaching of adults). We decided to use a **structured text** instead of a continuous one, as it is considered **more efficient in the process of studying, memorizing, and reviewing**. **We separated important anatomical information described in the main content from the less important**, which we put in the middle column. **Clinical correlations** have their place in the middle spread, as well. Special emphasis is put on **charts and schemes** serving as a tool for better memory consolidation and revision.

Steps of the Memorix Education System

1. Chapter structure
- schedule your study time and plan your study process
- look through the chapter headings, its divisions and subdivisions
- study the introduction windows and briefly look at pictures and schemes

2. Study the chapter in detail
- go through the chapter step-by-step
- reread the main sentences, study the main text and pictures carefully and in more detail
- try to find all the answers to your questions
- highlight all information which you consider to be important, make notes, redraw pictures and create mind maps

3. Interesting things
- look through the less important but interesting anatomical information in the middle column

4. Clinical notes
- read the clinical notes and try to understand the correlations between anatomy and clinical medicine

5. Schemes and charts
- use the schemes and charts for effective revision and quick orientation

6. Review questions and figures
- answer all the questions
- describe all the pictures presented in the revision part
- if you are not able to answer a question or describe a picture, return to the chapter and try to find it

7. Anatomy presenting
- present the information you have learnt to your classmates
- engage in discussions about the topics

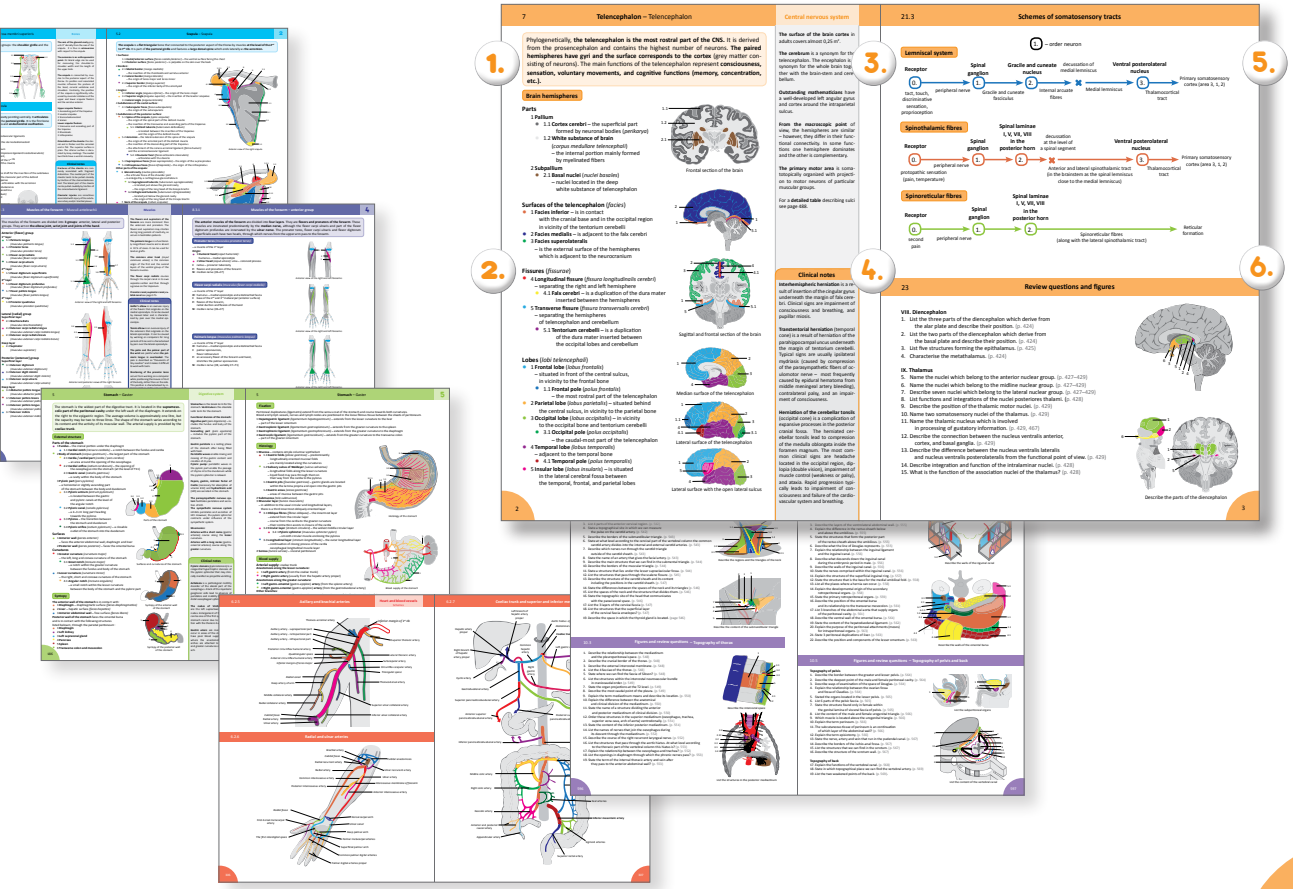

Designing a format, creating an outline, and building a quality team of authors, illustrators, and typesetters was just a fraction of the work. **Writing and constant efforts to improve the texts, illustrations, and schemes followed.** The integral part of the process was the involvement of **dozens of anatomists, clinicians, students, proofreaders, and native speakers** whose reviews and input have significantly contributed to the quality of our book. Certainly, we could not have sailed through all of this on our own. That is why **we would like to acknowledge all** who have contributed to the emergence of this revolutionary and unique anatomy textbook.

Firstly, we appreciate all of the time and energy of all the co-authors: **Jakub Miletín, Matej Halaj, Ladislav Douda, Barbora Beňová, Martin Čepelík, Vojtěch Kunc, Petr Vaněk, and Adam Whitley**. We are thankful for this hardworking team that made the Memorix Anatomy dream a reality. It was a great pleasure for the main authors to work with all of you.

We are grateful for our stunning illustrators, whose illustrative drawings and schemes make anatomy easier to understand and also visually attractive. Many thanks to the brilliant **Jan Balko** and precise **Šárka Zavazalová** for thousands of hours spent with electronic paintbrush, their ubiquitous tablets, and enthusiasm for colorful anatomy. We really appreciate the carthorse work of our typesetters, who are responsible for time-consuming manual corrections of all arising comments and revisions – many thanks to the tireless **Vojtěch Kunc**, tenacious **Matej Halaj**, and diligent **Daniel Slovák**. We also value very much the help of our certified language proofreaders: **Zuzana Balážová**, **Pavel Filip**, and **Michal Vilimovský** led by the extraordinary **Petr Vaněk**, and the willing native speakers led by the outstanding **Adam Whitley**; their cooperation and detective work contributed to the high-quality English in Memorix Anatomy. We appreciate all the help of our andragogist, **Miroslava Dvořáková**, who helped us with building of the Memorix Education System and who precisely answered all questions related to the didactic value of this textbook.

We wish to express our gratitude to all **anatomic reviewers** from all over the world, led by reviewer-in-chief and excellent clinical anatomist **Václav Báča**. Many thanks to **Nihal Apaydın** (Turkey), **Marcela Bezdíčková** (Czech Republic/Wales), **Susana N. Biasutto** (Argentina), **Phil Blyth** (New Zealand), **Adriana Boleková** (Slovakia), **Stephen Carmichael** (USA), **Ayhan Cömert** (Turkey), **Hans J. ten Donkelaar** (Netherlands), **Lada Eberlová** (Czech Republic), **Georg Feigl** (Austria), **Quentin Fogg** (Australia), **Guiliana Gobbi** (Italy), **Marek Joukal** (Czech Republic), **Dzintra Kažoka** (Latvia), **Darina Kluchová** (Slovakia), **Květuše Lovásová** (Slovakia), **Veronica Macchi** (Italy), **Pavel Šnajdr** (Czech Republic), and **Trifon Totlis** (Greece). Their contribution to Memorix Anatomy was always constructive and anatomically and personally enriching, and we cannot possibly thank them enough for all of the advice and suggestions they provided.

We very much value the help of **clinical reviewers**, who were able to contribute their precious time to Memorix Anatomy. Many thanks to physiotherapist **Zdeněk Čech** (Czech Republic), gynecologist **Andrej Černý** (Czech Republic), neuroradiologist **Christopher d'Esterre** (Canada), neurologist **Aravind Ganesh** (Canada), orthopedist **Vojtěch Havlas** (Czech Republic), cardiologist **Anna Chaloupka** (Czech Republic), gastroenterologist **Markéta Ječmenová** (Czech Republic), cardiosurgeon and vascular surgeon **Štepán Jelínek** (Czech Republic), internist **Dale Kalina** (Canada), neurologist **Robert Kuba** (Czech Republic), ophthalmologist **Helena Menšíková** (Czech Republic), urologist **Ivo Minárik** (Czech Republic), oncogynecologist **Lucie Mouková** (Czech Republic), internist **Jan Novák** (Czech Republic), neurologist **Eva Plaňanská** (Czech Republic), neurologist **Ondřej Strýček** (Czech Republic), and hematooncologist **Martin Štork** (Czech Republic). It was particularly their dedication, enthusiasm, and insight which has earned our frank gratitude and which has made this a better anatomy textbook with relevant and useful clinical notes.

Our gratitude also goes out to dozens of students who went carefully over the contents of the book page after page. They helped us discover quite a number of flaws and errors, thus improving the understanding of the entire text.

We wish to thank to **Memorix Anatomy godfathers**: **Vladimír Komárek** (Dean of Second Faculty of Medicine, Charles University in Prague, professor of neurology and Head of Department of Paediatric Neurology, Second Faculty of Medicine, Charles University in Prague and Motol University Hospital) and **Martin Bareš** (Vice-Rector for Development of Masaryk University in Brno, professor of neurology at First Department of Neurology, St. Anne's Faculty Hospital and Faculty of Medicine, and professor of neurology at University of Minnesota).

And last but not least, we are immensely appreciative of all anatomists, clinicians, students, and members of the Memorix team, who participated in the creation of the Czech predecessor of this book: Memorix Anatomie.

Finally, we would like to sincerely thank to our families, friends, and loved ones for the continuous help, unconditional support, and endless motivation.

Radovan Hudák, David Kachlík, Ondřej Volný

25 Anatomists

56 Medical doctors

94 Medical students

36 Other people

...worked hard creating MEMORIX ANATOMY for You!

Acknowledgements to co-workers

Anatomic reviewers

Assoc. prof. Václav Báča, MD, PhD
– *chief reviewer*
Assoc. prof. Nihal Apaydın, MD
Marcela Bezdičková, MD, PhD
Prof. Susana N. Biasutto, MD
Assoc. prof. Adriana Boleková, MD, PhD
Emer. prof. Stephen Carmichael, PhD, DSc.
Assoc. prof. Ayhan Cömert, MD
Prof. Hans J. ten Donkelaar, MD, PhD
Lada Eberlová, MD, PhD
Dr.med.univ. Georg Feigl
Quentin Fogg, PhD
Prof. Guiliana Gobbi , MD
Marek Joukal, MD
Assoc. prof. Dzintra Kažoka, MD
Prof. Darina Kluchová, MD, PhD
Assoc. prof. Květuše Lovásová, VDM, PhD
Assoc. prof. Veronica Macchi, MD, PhD
Pavel Šnajdr, MD, PhD
Trifon Totlis, MD, PhD

and further 4 anatomists which reviewed the Czech edition of Memorix Anatomy

Clinical reviewers

Zdeněk Čech, MSc.
Andrej Černý, MD
Christopher d'Esterre, PhD
Aravind Ganesh, MD
Assoc. prof. Vojtěch Havlas, MD, PhD
Anna Chaloupka, MD
Markéta Ječmenová, MD
Štepán Jelínek, MD
Dale Kalina, MD
Prof. Robert Kuba, MD, PhD
Helena Menšíková, MD
Ivo Minárik, MD, FEBU
Lucie Mouková, MD, PhD
Jan Novák, MD
Eva Plaňanská, MD
Ondřej Strýček, MD
Martin Štork, MD

and further 33 clinicians which reviewed the Czech edition of Memorix Anatomy

Student reviewers

Jan Brtek
Maxwell Cameron
Antonio Franca
Eva Fürstová
Therese George
Daniel Glanc
Monika Hejduková
Lucie Holubičková
Petr Kala
Linda Kašičková
Daanish Khorasani
Michal Klíma
Matěj Krchov
Adéla Kuklová
Vojtěch Kunc
Adam Kubica
Miroslav Kyselica
Verena Leppmeier
Lukáš Mach
Domenico Messina
Klára Macháčková
Lucie Mládenková
Lenka Molčányjová, MSc.
Shannon Motsuka, MSc.
Ramkumar Nagarajan
Jakub Ivan Němec
René Novysedlák
Lucie Olivová
Dominik Paugsch
Emilía Petríková
James Sherrington
Sebastian Schmitz
Kateřina Tomanová
Petr Urban
Prokop Vodička
Christoph Wawoczny
Rachel White
Danil Yershov

and further 52 medical students which reviewed the Czech edition of Memorix Anatomy

Others

Prof. Vladimír Komárek, MD, CSc.,
Prof. Martin Bareš, MD, PhD
Dr. Miroslava Dvořáková, Ph.D.
Stanislav Juhaňák, MD
Gabriela Holubová
Peter Magic
Helena Menšíková, MD
Michaela Pospěchová
Daniel Slovák
Prokop Vodička

The creation of the Czech and English version of Memorix Anatomy involved together over 200 people. We sincerely thank you from the depths of our anatomical hearts.

Acknowledgements to student organisations

Student clubs bring together active students to work, create, and help with enthusiasm. These organizations prepare unique projects that **educate students, elicit smiles on the faces of patients, and inform thousands of fellow citizens about health care**. Members of these organizations are not paid for their work, but **their reward is the feeling of a job well done, the gained experiences, and the possible appreciation from others**. I myself, as well as many co-authors, are grateful to many of these associations for what they have taught us about communication, time and projects management, teamwork and many other areas. If it weren't for student organizations and active students, this book would have never been created. We thank you.

IFMSA Czech Republic (IFMSA CZ), the largest medical student organisation in the Czech Republic, is a part of IFMSA, a federation of medical student organisations spanning the world. Projects like Medicafé, Teddy Bear Hospital, World Health day and many others, provide medical students with first hand experience dealing with public health and many other topics. IFMSA CZ also holds successful fundraising events, that help various non-profit organisations. IFMSA CZ organises more than 300 clinical and research exchanges yearly. These exchanges are open to all our members, giving them an opportunity to travel, meet other cultures, whilst furthering their medical knowledge and experience. www.ifmsa.cz

Slovak Medical Student's Association (SloMSA) connects 4 Local Medical Student's Associations in Slovakia and provides projects in public health, medical education, reproductive health and in many other fields of medicine. Our Association also provides more than 150 month exchange programs for medical students to more than 40 countries worldwide every year. www.slomsa.sk

Editors – anatomy is our passion, anatomy is our life

Radovan Hudák

I devoted my childhood to basketball, which I played at a professional level, but a **knee injury changed my life course towards medicine**. Sports have continued to stay in my heart and have shifted me to **medical disciplines related to the construction and movement of the human body**, such as **anatomy, kinesiology and orthopedics**. In medical school I was actively involved in **student organisations and the academic senate** and in the third year of my medical studies, **I started teaching anatomy**. My goal is to **teach students in both a fun and an easily understood manner**. I like active people and I try to be one of them. I guess **I'm a workaholic** but I love it.

David Kachlík

During my medical studies at university, the true, **decisive and fatal crossroad of my life came into the picture: the dissection room**. That space destined my future life career and medical specialization. **Fascination by the hidden corners and nooks of the human body** led me to my future teaching and scientific way of life. The driving force of my effort was the desire to **mediate the knowledge to students in an easily accessible and gripping manner**. Whenever I saw a light of cognition in my students' eyes, my endeavor came to fruition. **The result of my effort is this book**. Although it pulled me away from my children a bit, **it became a kind of my child itself**.

Ondřej Volný

I was born in Ostrava, where I have graduated from both elementary and high school. After that, my feet lead me to Brno to the Medical Faculty. **My big dream is to one day be on the world's stage**, though I haven't yet tried actual acting. Instead, every week I **„perform" in front of students during anatomy classes**. I like challenges, which is why I chose **the brain and nervous system as a chapter in Memorix, as well as in my professional life**. I focused on neurology, anatomy, and research at **Hotchkiss Brain Institute at the University of Calgary**. Currently, I work as an assistant professor at the **First Department of Neurology in Brno**.

Co-authors – nothing fascinates us more than the mysteries of human anatomy

Barbora Beňová

Starting as a young and eager book-loving student of medicine, as soon as I could **I immersed myself into the complexity of anatomy** bringing it to today's young, eager and book-loving students. Working as an anatomy assistant I was offered a wonderful chance to co-author this amazing textbook. **The complexity of human anatomy strikes me every day in my practice**. Currently as **a resident of paediatric neurology and a PhD student in neuroscience**, I turn back to the very first edition of "Memorix Anatomie" to recall all the lost and newly regained knowledge of brain anatomy.

Martin Čepelík

Since childhood as I remember I have always wanted to become a physician. I have also been **inclined to teaching and anatomy** united these two paths into one. Although I am now working as **a surgeon in the Department of Pediatric Trauma and Surgery** in Prague, I still gladly remember my days in the Department of Anatomy, and **my knowledge of anatomy helps me a lot in what I do now**. I am proud and thankful to be a part of such great team that worked hard on the Memorix Anatomy and I hope that **it will be as rewarding for you to read it as it was for us to create it**.

Ladislav Douda

The relationship between structure, function and clinical relevance is the main goal of studying and teaching anatomy. The ability to explain, to answer frequently asked questions and anatomical difficulties, and simply to be closer to the readers and behave student-friendly, these are the rudiments of Memorix Anatomy. **This excellent textbook makes studying anatomy interesting and dynamic**. In this matter, it not only deserves an exceptional attention but also an exceptional humility of authors before their own work.

Co-authors – nothing fascinates us more than the mysteries of human anatomy

Matej Halaj

After years of hard work in judo, hockeyball and contemplating studying at lawschool, I decided to leave it all behind and **instead pursue medschool**. As a medical student I get the opportunity to **teach anatomy at our anatomy department in Brno**. It was something remarkable for me. That's the reason why I said: "Yes!" when Rado Hudák asked me, if I wanted to work on Memorix Anatomy. Currently **I work as a resident of Neurosurgery** in Olomouc and **I open Memorix almost every day**. I hope that anatomy with **Memorix will soon become your passion**.

Vojtěch Kunc



"Do you like it?" With this question one Georgian orthopedist **asked for my opinion after a complicated surgery**. I laughed. Why would an experienced surgeon ask a newbie, who was only seeing that operation for the first time? But it was not a joke. **The surgery was not finished until every member of the team verified that he or she was satisfied by it**. This humble attitude I have also found this humble attitude within the **Memorix team**. **Both are connected by the desire for perfection**. I hope this book will serve you well and I would also like to ask you: **do you like it?**

Jakub Miletín

I have been interested in surgery and anatomy since my first years at the university. Thanks to the friendly attitude of the department of anatomy, **I had almost unlimited options to study this wonderful discipline**. **Its knowledge helps me a lot in my surgical profession**, so I decided to continue teaching anatomy at the Third Faculty of Medicine. **I always try to transmit my knowledge to the students in as a comprehensible way as possible**. Memorix Anatomy was **a great challenge to be able to explain the topographical anatomy intelligibly, yet still thoroughly**.

Petr Vaněk

I am ambitious and have been since an early age. As a child, I grew up **dreaming of playing sports** in the pro-ranks and couldn't picture myself doing anything else. Later on, I moved to the United States and began to fulfill this dream. But there is one saying, "**We plan, God laughs.**" And so, after a series of injuries, my sports career was over. This life lesson, which has taught me much about the importance of health, has brought me a new ambition: **restoring the health of others**, which after all, may be **more rewarding than anything else**. And **it all begins with anatomy**.

Adam Whitley

I was inspired to teach anatomy by the excellent student lecturers who taught me during the dissection course in my first year of studies. I grew up in England, and moved to Prague in 2010 **to study at the Second Faculty of Medicine at Charles University**. I have now been teaching anatomy for four years and I have taught students of both the second and first medical faculties. **I have enjoyed working on Memorix Anatomy and I believe it provides a unique way of presenting the complexities of human anatomy in a simple and concise format**.

Illustrators – a drawing of the human body is a pleasure of our senses

Jan Balko

I have taken part in creation of Memorix Anatomy right before my graduation. It has been my task to **paint the majority of the pictures including the cardiovascular system, bones, joints** etc. Luckily, there were two co-workers, who helped me a lot. We have managed to **finish hundreds of pictures in just a single year**. It was our wish to **make them simple and colourful**. **Simplicity makes it possible to redraw the pictures by the students themselves** and **the motley colours help distinguish all the anatomical structures**. I hope you will be satisfied with our work.

Šárka Zavázalová

For a long time the **only partnership between me and medicine was an emergency room and an otorhinolaryngology ward**. At present, as a physician, I gain strength for **doing my job through my lifetime hobby – drawing and painting**. I'm extremely happy that I was challenged to utilize my hobby by **making illustrations for this marvellous textbook – friendly not only to medical students but also to forgetful physicians** – as well as myself. I hope this book will accompany you on your journey through medical school and medical career.

”Everything should be made as simple as possible,
but not simpler.“

Albert Einstein

Memorix Anatomy

1 General anatomy

David Kachlík
Radovan Hudák
Ondřej Volný
Adam Whitley

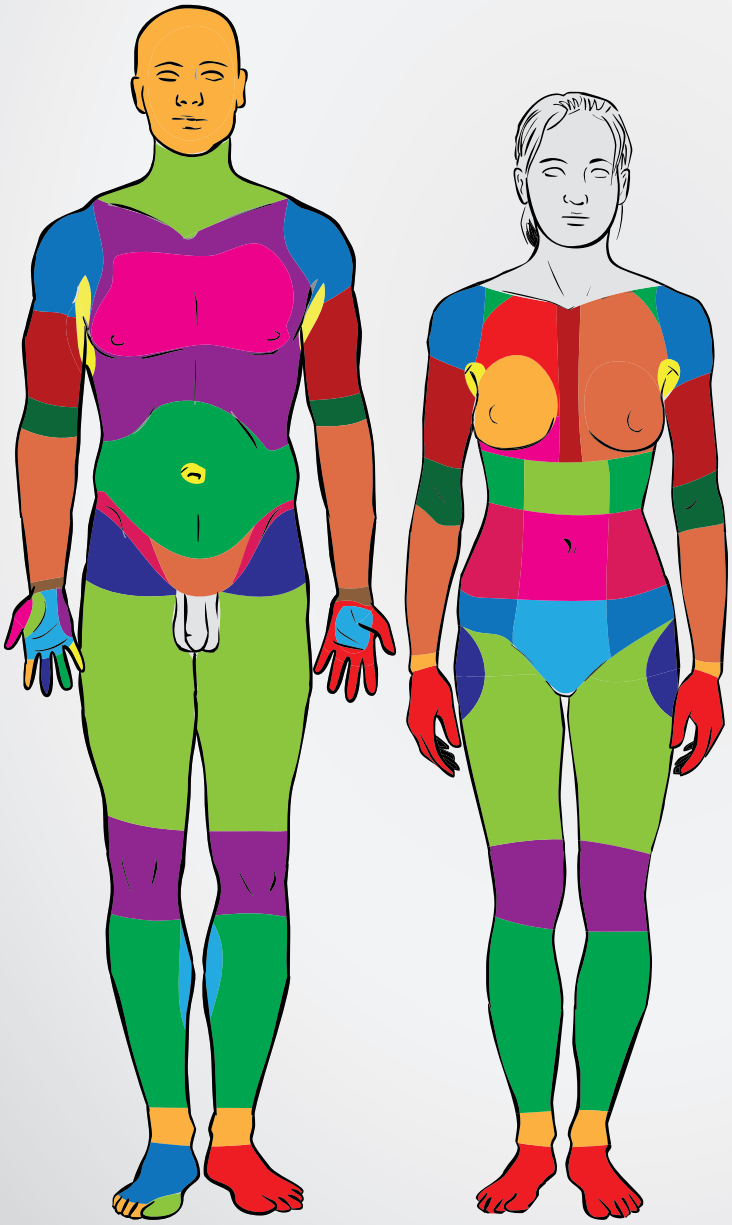

Anatomy is a scientific field concerned with the structure of the human body. The term "anatomy" comes from the Greek "**anatemnein**", which literally means "to cut". Anatomy describes the shape, internal structure and location of the individual parts of the body to enable an understanding of their function, demonstrating that structure and function are inseparably connected. As a **preclinical science**, it provides the foundation for of all fields of clinical medicine. We – medical students, physiotherapists, nurses and physicians – would not be able to get by without anatomy and that is why we keep coming back to it.

Definitions

Morphology – a scientific field that includes anatomy, histology and embryology
– a study of the structure and development of the human body
Anatomical terminology – terms describing particular parts of the human body
Anatomical nomenclature – international official anatomical terminology in Latin
Terminologia anatomica (TA 1998) – the most recent version of the anatomical nomenclature
Obsolete terms – terms that have been replaced or removed from the terminologia anatomica
Eponyms – anatomical terms named after living, dead or fictitious people
– terms usually named after the person who first described or discovered the structure
– in clinical medicine some eponyms are used more frequently than the Latin terms
Standard/norm – a set of characteristics occurring most often
Variation – a small deviation from the standard without any functional changes
Anomaly – a significant deviation from the standard causing functional changes

Classifications

According to size:

Macroscopic anatomy – description of the body with the naked eye or with small magnification
Microscopic anatomy/histology – description of the body with the use of microscopic technology
– description of stained slices of tissue viewed under the microscope

According to function:

Normal – study of the structure of the healthy human body
Pathological – study of the anatomical changes that occur with disease

Subspecialities of anatomy:

Systematic anatomy – description of organs according to their development and structure
Topographic anatomy – description of the spatial relationship of different organs to each other and their placement in the body

Others:

Clinical/applied anatomy – use of anatomical findings in clinical medicine
Surface anatomy – description of how the surface of the body appers to the naked eye
– description of body proportions
Comparative anatomy – description of the similarities and differences in the anatomy of humans and animals

World history

1600 B.C.	**Egypt**	**Erbs papyrus** the first description of the heart, vessels and some other organs and diseases
460–377 B.C.	**Greece**	**Hippocrates of Kos** performed the first human anatomical descriptions
384–322 B.C.	**Greece**	**Aristotle of Stageira** described the differences between arteries and veins and performed animal dissections
335–280 B.C.	**Greece**	**Herophilos and his student Erasistratos** performed the first human dissection
1st century B.C.	**Greece**	**Rufus of Ephesos** wrote the first book of anatomical terminology
129–205/211	**Rome**	**Galen of Pergamon** performed dissections on animals and the first detailed anatomical works
980–1037	**Persia**	**Avicenna** wrote "The Canon of Medicine", the definitive textbook of medicine in the Middle Ages
1213–1288	**Egypt**	**Ibn al-Nafis** wrote the first description of the pulmonary circulation and capillaries
1514–1565	**Italy**	**Andreas Vesalius** wrote the first modern anatomy textbook "De humani corporis fabrica" in 1543

Anatomy is a descriptive science that almost universally uses mainly **Latin and Greek terms.** Every term has an **English equivalent**. Many of the English equivalents are similar to the Latin, but some are completely different. As Latin is still the first language of medical terminology, **it is important to know at least the basic terms in both languages.**

Basic terms (latin – english)

Abdomen – abdomen, belly
Ala – wing
Angulus – angle
Apex – apex, top
Arcus – arc
Arteria – artery
Articulatio – joint
Brevis – short
Canalis – canal
Capitulum – small head
Caput – head
Cartilago – cartilage
Cauda – tail
Cavitas – cavity
Caecus – blind
Cerebrum – brain
Cervix – neck
Circumferentia – circumference
Collum – neck
Cornu – horn
Corpus – body
Costa – rib
Cranium – cranium
Crista – crest
Dexter – right
Dorsum – back, dorsum
Ductus – duct
Eminentia – prominence, eminence
Et – and
Excavatio – pouch
Extensor – extensor (muscle)
Extremitas – extremity
Facies – surface
Fissura – fissure
Flexor – flexor (muscle)
Foramen – foramen, opening
Fossa – fossa, hole, pit
Fovea – pit, snare
Ganglion – ganglion
Glandula – gland
Hallux – toe
Hiatus – opening in organ
Impressio – impression
Incisura – notch
Interosseus – located between bones
Labium – lip
Latus – flank
Ligamentum – ligament
Linea – line
Longitudinalis – longitude
Longus – long
Lympha – lymph
Magnus – big
Major – greater
Manus – hand
Margo – border
Maximus – the biggest
Medulla – marrow
Membrum – limb
Minimus – the smallest
Minor – lesser
Musculus – muscle
Nervus – nerve
Nucleus – nucleus
Nutritium – nourishing
Nodus – node
Obliquus – oblique
Os – bone
Os – mouth
Ostium – entrance, opening
Paries – wall
Pars – part
Parvus – small
Pelvis – pelvis
Pectoralis – pectoral, related to chest
Pectus – front of chest
Planum – plane
Plexus – plexus
Pollex – thumb
Processus – process
Profundus – deep, profound
Prominentia – prominence
Ramus – branch
Rima – crack, fissure
Seu – i.e / in other words
Sinister – left
Sinus – cavity, hollow, sinus
Septum – enclosed place, septum
Spatium – space, room
Spina – spine
Sulcus – groove
Superficialis – shallow, superficial
Recessus – space, recces
Tendo – tendon
Teres – rounded, teres
Thorax – chest, thorax
Tonsilla – tonsil
Transversalis – transverse
Truncus – trunk
Tuber – hump, tuber
Tuberculum – small bump, tubercle
Tuberositas – tuberosity
Vas, vasa – vessel
Vena – vein
Venter – belly
Vesica – bladder
Vertebra – vertebra

Basic abbreviations

a. – aa. (arteria – arteriae)
v. – vv. (vena – venae)
n. – nn. (nervus – nervi)
lig. – ligg. (ligamentum – ligamenta)
m. – mm. (musculus – musculi)
proc. – procc. (processus – processus)
r. – rr. (ramus – rami)
n. l. – nn. l. (nodus lymphoideus – nodi lymphoidei)
art. – artt. (articulatio – articulationes)
ncl. – ncll. (nucleus – nuclei)
gl. (glandula)
ggl. (ganglion)
pl. (plexus)
ant. (anterior)
post. (posterior)
int. (internus)
ext. (externus)
med. (medialis)
lat. (lateralis)
sup. (superior)
inf. (inferior)
prof. (profundus)
supf. (superficialis)
dx. (dexter)
sin. (sinister)
l. sin. (lateris sinistri) – of the left side
l. dx. (lateris dextri) – of the right side
ANS – autonomic nervous system
CNS – central nervous system
ENS – enteric nervous system
PNS – peripheral nervous system
GIT – gastrointestinal tract
UGT – urogenital tract
UL / LL – upper limb / lower limb

Histology is a science that describes cells, tissues, organs and organ systems on a microscopic level. **The cell is the fundamental unit of the body.** During development cells come together to form tissues. **A tissue** is a set of cells and extracellular matrix with a specific function. **There are four types of tissues** that combined together form **organs**. A set of organs forms **an organ system**, which is characterised by its specific functional characteristics.

The cell *(celulla)*

The eukaryotic animal cell is the structural and functional unit of the human body.

- 1 **Plasmalemma / cell membrane** – the envelope of the cell
  – a biomembrane made up of a phospholipid bilayer
  – is semi-permeable and regulates the transport of substances into and out of the cell
- 2 **Cytoplasm** – contains the cytosol, organelles, cytoskeleton and cellular inclusions
  3 **Organelles** – structures in the cytoplasm that are surrounded by biomembranes
  - 3.1.**Mitochondria** – produce energy for the cell
  - 3.2 **Rough/granular endoplasmic reticulum (RER)** – contains ribosomes on its surface
    – produces and modifies proteins, which are destined to become parts of the cell or are exported into the extracellular matrix
  - 3.3 **Smooth/agranular endoplasmic reticulum (SER)** – synthesises steroids, membrane proteins and glycogen
    – the SER in liver hepatocytes carries out detoxification
    – the SER in skeletal muscle cells stores calcium ions
  - 3.4 **Golgi complex** –performs posttranslational modification and packaging and secretion of proteins
  - 3.5 **Lysosome** – degrades intracellular and extracellular proteins
  - 3.6 **Peroxisome** – contains a lot of enzymes and takes part in detoxification
    – degrades fatty acids and amino acids
- 4 **Nucleus** – contains genetic material in the form of chromatin
  - 4.1 **Nucleolus** – a structure within the nucleus that synthesises ribosomes
- 5 **Ribosome** – is located in the cytoplasm and creates proteins for the needs of the cell
- 6 **Cytoskeleton** – a network that supports the shape and functions of the cell
  6.1 **Microfilaments** – orchestrate cellular movement and intracellular transport
  6.2 **Intermediate filaments** – provide integrity and support to the cell
  6.3 **Microtubules** – facilitate intracellular transport
- 7 **Cytoplasmic inclusions** – deposits of lipids, saccharides, proteins or pigments
  – are either produced by the cell or acquired from outside the cell

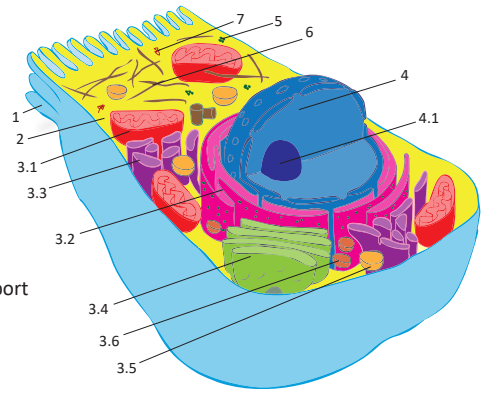

Eukaryotic cell

Tissues *(textus)*

1 **Epithelial tissue** – an avascular tissue, made of tightly connected cells and very little extracellular material
– is separated from other tissues by the basal lamina
– has three major characteristics: number of cell layers, height of the cells and cell surface apparatus (microvilli, kinocilia and stereocilia)
1.1 **Surface epithelium** – has a protecting and supporting function, forms mucous membranes and covers the surface of the body
1.2 **Glandular epithelium** – makes up endocrine glands, which secrete their contents into the blood and exocrine glands, which secrete their contents into body cavities or onto the body surface
1.3 **Specialised epithelium** – includes sensory neuroepithelium and the epithelial part of the thymus
2 **Connective tissue** – has mechanical, protective and supporting functions
– consists of cells in a variable amount of extracellular material know as the extracellular matrix
– the extracellular matrix has a fibrillar component of collagen and elastic fibers and an amorphous component of glycosaminoglycans
2.1 **Connective tissue proper** – possesses many cells in an extracellular matrix and has a gel-like consistency
2.1.1 **Loose connective tissue** – fills spaces between organs and can be found in the walls of organs beneath the mucosa
2.1.2 **Dense connective tissue** – makes up ligaments, tendons and articular capsules
2.2 **Cartilage tissue** – is composed of cells in an extracellular matrix and has a solid but elastic consistency
2.2.1 **Hyaline cartilage** – is located on the contact surfaces of bones inside joints and forms epiphyseal growth plates
– is integral in the process of bone healing, is found in the wall of the trachea and bronchi and forms part of the ribs
2.2.2 **Fibrous cartilage** – is found in intervertebral discs and in the pubic symphysis
2.2.3 **Elastic cartilage** – is found in the auricle of the ear and in the epiglottis
2.3 **Bone/osseous tissue** – is composed of a small proportion of cells in a firm extracellular matrix that is mineralised by calcium
3 **Muscle tissue** – is made up of cells that contain myofibrils (actin and myosin), which give them the ability to contract
3.1 **Smooth muscle tissue** – is found in the walls of organs and vessels and is innervated by the autonomic nervous system
3.2 **Skeletal striated muscle tissue** – is located on the skeleton and innervated by somatomotor cranial and spinal nerves
3.3 **Striated cardiac muscle** – is found only in the heart and has its own electrical conduction system
4 **Nerve tissue** – is made up of neurons and supporting cells (neuroglia)
4.1 **Neurons** – cells that are able to accept, process and transmit impulses
4.2 **Neuroglia** – protect and support neurons
+ **"Liquid/trophic tissue"** – comprises interstitial fluid, blood and lymph

Embryology is a scientific field concerned with the **creation and development of the embryo and foetus, all the way from a fertilised oocyte to birth**. Embryology also deals with anomalies that occur during development that give rise to **congenital defects**. The **3 germ layers** arise during the third week of the development in the form of the **trilaminar germ disc**, which comprises the endoderm, mesoderm and ectoderm. **The pharyngeal arches** originate from mesenchyme as pairs of arc–shaped prominences **in the region of head and neck** of the embryo during the fourth and fifth week of development.

Developmental periods

1. **Prenatal/gestation/intrauterine period** – extends from fertilisation to birth
   1.1 **Fertilisation** – the process of fusion of an egg and a sperm to form a zygote
   1.2 **Blastogenesis** – occurs during the first two weeks after the fertilisation
   – under unfavourable external influences only two things can happen following the "all or nothing principle": either the embryo will survive or it will be aborted
   1.3 **Embryonic period** – extends from fertilisation to the end of the eighth week
   – all organ systems are formed
   – the embryo is most vulnerable to toxic, radioactive, metabolic, pharmacological and other influences that may cause developmental defects
   1.4 **Foetal period** – extends from the end of the 8th week to birth
   – the organ systems continue to grow and develop
2. **Perinatal period** – starts at the beginning of the 28th week of intrauterine development and ends one week after birth
3. **Postnatal period** – extends from birth to death

Primary germ layers

1 **Ectoderm** – the outer layer of the trilaminar germ disc
– differentiates to form epithelial tissues including the epithelium of the skin and its appendages (hair, nails and sweat glands), the epithelium of the inital and terminal parts of the gastrointestinal tract, the adenohypophysis and the neurogenic placodes
1.1 **Neuroectoderm** – a derivative of the ectoderm that gives rise to the neural tube and the neural crest
– the neural tube differentiates into the brain and the spinal cord
– the cells of the neural crest migrate to various part of the body
– the neural crest forms the peripheral nerves and ganglia, fibrous tissue in the head and neck, melanocytes, the receptors cells of the carotid body, the medulla of the suprarenal glands and some structures in the heart

2 **Mesoderm** – the middle layer of the trilaminar germ disc
2.1 **Paraxial mesoderm** – forms somites, which develop into bones, muscles and the dermis
2.2 **Intermediate mesoderm** – forms the urogenital tract
2.3 **Lateral plate mesoderm** – forms the body wall
+ **Mesenchyme** – embryonic connective tissue that forms vessels, smooth muscles, haematopoietic tissue and mature connective tissue

3 **Endoderm** – the inner layer of the trilaminar germ disc
– gives rise to the epithelium of the liver, pancreas, gastrointestinal tract (apart from the mouth, nasopharynx and anus), auditory tube, trachea, bronchi, alveoli, urinary bladder, upper part of the urethra, thyroid gland, parathyroid glands and thymus

Pharyngeal arches *(arcus pharyngei)*

Each pharyngeal arch contains an artery, muscle tissue, a cranial nerve and a connective tissue element of cartilage, ligament or bone.

- 1 **First pharyngeal arch**
  bones: mandible, maxilla, zygomatic bone, malleus and incus
  muscles: masticatory muscles, anterior belly of the digastricus, mylohyoid, tensor veli palatini and tensor tympani
  cranial nerve: trigeminal nerve
  artery: terminal part of the maxillary artery
- 2 **Second pharyngeal arch**
  bones: stapes, styloid process and the lesser horn and upper part of the body of the hyoid bone
  muscles: mimetic muscles, platysma, stapedius, stylohyoid and the posterior belly of the digastricus
  cranial nerve: facial nerve; **artery:** stapedial artery
- 3 **Third pharyngeal arch**
  bones: greater horn and the lower part of the body of the hyoid bone
  muscles: stylopharyngeus
  cranial nerve: glossopharyngeal nerve;
  artery: common carotid artery and the first part of the internal carotid artery
- 4 **Fourth and sixth pharyngeal arch**
  cartilage: laryngeal skeleton
  muscles: musculature of the pharynx and larynx
  cranial nerve: vagus nerve - the superior laryngeal nerve is from the 4th arch and the recurrent laryngeal nerve is from the 6th arch
  artery: the aortic arch and right subclavian artery are from the 4th arch and the pulmonary arteries and ductus arteriosus are from the 6th arch

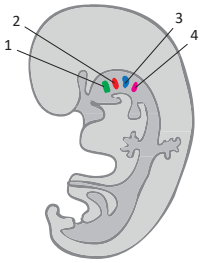

Pharyngeal arches in the embryo

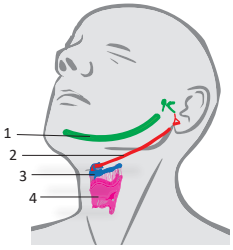

Derivatives of the pharyngeal arches

In comparison to other animals, **the human undergoes an extraordinary process of growth and development during childhood and puberty**. The two major periods of acceleration of growth are in **infancy** and **puberty**. Growth in-between these periods is slower. This allows time for the child to develop psychologically before undergoing **full physical transformation into adulthood**. Organs and organ systems grow both **isometrically** (proportionally) and **allometrically** (disproportionally) in relation to other organs and organ systems.

Head

Proportions of the head to the rest of the body
– the head forms half the length of the embryo in the 6th–7th week of intrauterine development
– the length of the head equals one quarter the length of the newborn at birth
– the circumference of the head and thorax are equal by the 5th month of life and from this moment onwards the thorax will grow faster
– the head is the fastest growing part of the body in the 1st year of life
– the head forms about one eighth the length of the body in adulthood

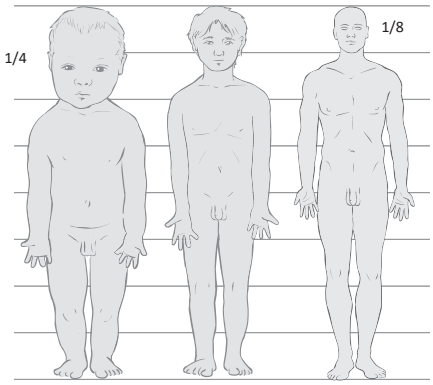

Thorax

Heart – in childhood, the proportion of the weight of the heart to the rest of the body is about twice as high as it is in adulthood
Lungs and respiratory passage – the lower respiratory tract elongates until the 1st year and then enlarges only in diameter
– the number of alveoli increases until the 8th year of life and then only increase in size
Oesophagus – is about half the length of the trunk in newborns
– is about one quarter the length of the trunk in adults

Abdomen

Stomach – the ratio of the weight of the stomach to the rest of the body is highest in children
Liver – forms about 5 % of body weight in children and about 2.5 % of body weight in adults
Kidneys – the final number of nephrons is reached by the 35th–36th week of intrauterine development
Testes – are formed in the lumbar region
– in the 3rd month of intrauterine development, the unequal growth of the thorax and the traction of the gubernaculum testis begin to move the testes caudally through the retroperitoneum and inguinal canal into the scrotum
– by the 8th month of intrauterine development, the testes are fully descended in the scrotum

Central nervous system

The weight of the brain – about 300–400 g in newborns or approximately 10 % of total body weight
– gyri and sulci appear on the surface of the cerebral cortex in the 4th month of intrauterine life
– reaches 75 % of the weight of an adult brain by the end of the 1st year of life
– reaches 100 % the weight of an adult brain in the 15th year of life
– the adult brain weighs 1300–1400 g, which is approximately 2% of total body weight
– the increase in brain weight after birth is caused mainly by myelination and an increase in the number of neuroglial cells
Spinal cord – is as long as the vertebral canal at the start of embryonic development
– the vertebral canal grows faster than the spinal cord from the 3rd month of intrauterine development
– the spinal cord therefore does not fill out the whole length of the vertebral canal
– the final level of the caudal border of the spinal cord is L1 – L2

General anatomy

The anterior fontanelle *(fonticulus anterior)* closes during the 1st–3rd year of life. **The posterior fontanelle** *(fonticulus posterior)* usually closes by the 3rd month of life. However it may already be closed at birth.

The volume of cerebrospinal fluid in a newborn born by a spontaneous vaginal delivery is about half that of a newborn born by a Caesarean section. During the baby's passage through the birth canal, the cerebrospinal fluid is forced into the venous sinuses.

The menarche is the onset of menstruation in girls. It is one of the first signs of puberty and appears between the 10th–17th year of age. In Central Europe, it usually occurs between the 12th–13th year of age. In the last couple of decades sexual maturation has been occurring progressively earlier.

The onset of puberty has been occurring earlier in life and the average height of the population has been steadily increasing over the last century. This phenomenon, known as **"the secular trend of puberty''** has been attributed to a better quality of nutrition.

The skull of a newborn is discussed on page 35.
The descent of testes is discussed on page 241.
The anatomy of pregnancy, the embryo and birth are discussed on page 257.
Vertebromedullary topography is described on page 398.
Psychomotor development is discussed on page 478.
The breast and mammary gland is described on page 517.

Clinical notes

A prominent pulsating fontanelle can be a sign of increased intracranial pressure, meningitis or other serious conditions. A sunken fontanelle on the other hand can indicate poor hydration of the baby.

Premature puberty *(pubertas praecox)* is characterised by onset of secondary sex characteristics before the 8th year in girls and before the 9th year in boys. It occurs in about 0.6 % of all children, more often in girls.

Pubertas tarda is a term for delayed puberty.

During puberty, the process of **psychosomatic maturation** of a child into an adult takes place. This process is accompanied by a set of **anatomical and physiological changes** that are integrally linked to each other. Using these changes to evaluate the stage of puberty is far more informative than relying solely on the age of the child. The onset of these changes can vary in children of the same sex in the range of 3–4 years. Generally speaking, **puberty starts in males 1–2.5 years later than in females**. **The Tanner scale** is commonly used to assess the level of changes occurring during puberty. In males, the growth of pubic hair, testes, penis and scrotum are evaluated. In females, development of breasts and the growth of pubic hair are evaluated.

Pubic hair in both genders

Stage Ph1 (< 10 years of age)
– no pubic hair
Stage Ph 2 (10–11.5 years of age)
– a small amounts of long fine weakly pigmented hair located around the root of the penis and the scrotum in males and on the mons pubis and labia majora in females
Stage Ph 3 (11.5–13 years of age) – the hair becomes darker, thicker and curly and spreads out on the skin overlying the pubic symphysis
Stage Ph 4 (13–15 years of age)
– the pubic hair is of adult type in quality, but in a smaller amount than in an adult
– in girls, the pubic hair covers a triangular shaped area of skin on the mons pubis and labia majora
Stage Ph 5 (>15 years of age)
– pubic hair of an adult, grows on adjacent parts of thighs
– female type: the upper border of the pubic hair is sharp and horizontally straight
– male type: usually continues cranially in a narrow triangle reaching as high as the navel

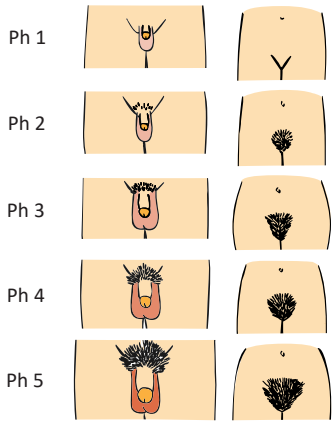

Male external genital organs

Stage G 1 (< 9 years of age)
– the volume of the testes is less than 1.5 ml
– the size of penis is 3 cm or less
Stage G 2 (9–11 years of age) – the volume of the testes is 1.6–6 ml
– the scrotum and testes enlarge
– the skin of the scrotum becomes thinner, wider and reddish
– the length of the penis remains unchanged
Stage G 3 (11–12.5 years of age) – the volume of the testes is 6–12 ml
– the scrotum and penis enlarge
– the penis grows to about 6 cm in length
Stage G 4 (12.5–14 years of age) –the volume of the testes is 12–20 ml
– the scrotum enlarges and becomes darker coloured
– the penis grows to about 10 cm in length
– the rate of growth of the width of the penis increases
Stage G 5 (> 14 years of age) – the volume of the testes is greater than 20 ml
– the external genital organs reach adult size and shape
– the length of the penis is approximately 15 cm

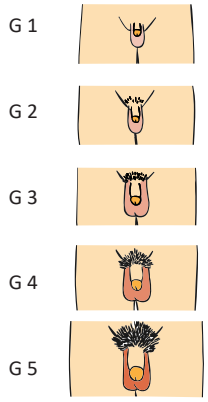

Male external genital organs

Female breast

Stage M 1 (<10 years of age) – *mamma puerilis / mamma neutralis*
– no gland tissue is present
– the unpigmented areola is in the same plane as the skin
Stage M 2 (10–11.5 years of age) – *mamma areolata*
– a small mass of glandular tissue is palpable in the area of the areola
Stage M 3 (11.5–13 years of age) – the breast is pointy and cone-shaped
– the gland grows beyond the margins of the areola
Stage M 4 (13–15 years of age) – the areola is raised above the plane of the skin
– the areola is slightly pigmented
– the areolar tubercles of the areolar glands are not visible
– the nipple is not yet erectile
Stage M 5 (>15 years of age) – the definitive appearance of a mature breast
– the areola is again in the same plane as the skin
– the areola is hyperpigmented
– the areolar tubercles are visible on the surface of the areola
– the nipple is erectile

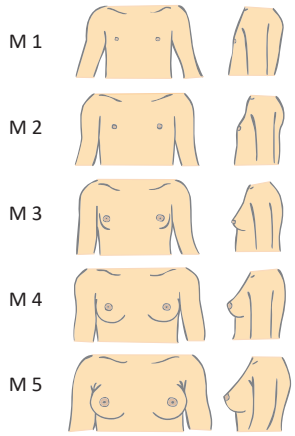

Female breast

To avoid confusion, the structures of the human body are described in a specific posture. This posture is called **the anatomical position and is an upright posture with the upper limbs on the sides of the body with the palms facing forward.** To help us orientate structures on the human body, we use **three principle perpendicular planes of reference**. These are the sagittal plane, the frontal plane and the transverse plane. **The sagittal plane** runs through the body from the back to the front. **The frontal plane** is parallel to the forehead and divides the body into posterior and anterior portions. **The transverse plane** runs through the body horizontally, dividing it into cranial and caudal portions. **The mid-sagittal or median plane** is a sagittal plane found **exactly at the midpoint of the body** and cuts the body into **symmetrical left and right halves.**

Planes of the human body *(plana corporis humani)*

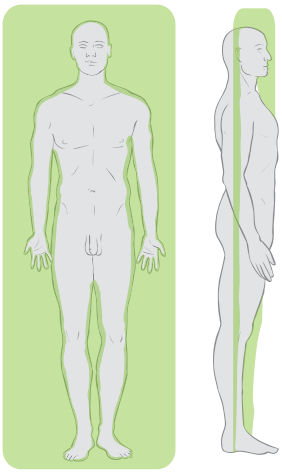

● **Frontal plane** / coronal plane (*planum frontale*)

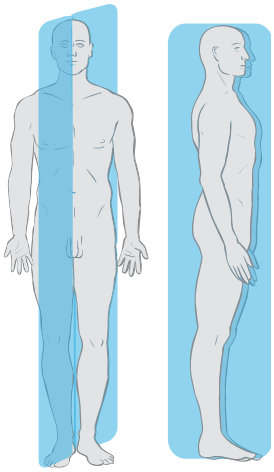

● **Sagittal plane** (*planum sagittale*)

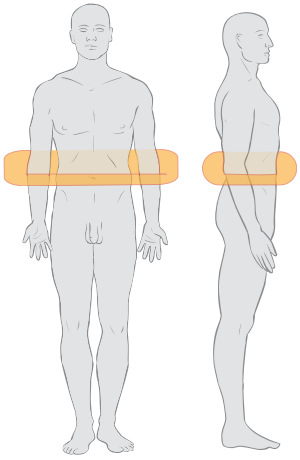

● **Transverse plane** / horizontal plane / axial plane / cross-section (*planum transversalium*)

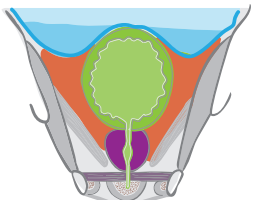

Frontal section of the male pelvis

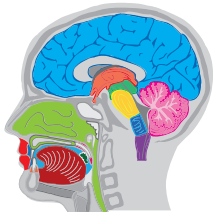

Sagittal section of the head

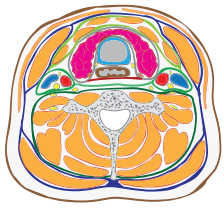

Transverse section of the neck

Lines of the human body *(lineae corporis humani)*

- 1 **Anterior median line** *(linea mediana anterior)* – runs vertically through the centre of the thorax and abdomen
- 2 **Sternal line** *(linea sternalis)* – runs vertically along the lateral side of the sternum
- 3 **Parasternal line** *(linea parasternalis)* – runs vertically in-between the sternal and midclavicular line
- 4 **Midclavicular line** *(linea mediocla vicularis)* – runs vertically through the midpoint of the clavicle
- 5 **Anterior axillary line** *(linea axillaris anterior)* – runs vertically through the anterior axillary skin fold
- 6 **Midaxillary line** *(linea axillaris media)* – runs vertically through the apex of the axilla
- 7 **Posterior axillary line** *(linea axillaris posterior)* – runs vertically through the posterior axillary skin fold
- 8 **Scapular line** *(linea scapularis)* – runs vertically through the middle of the inferior angle of the scapula
- 9 **Paravertebral line** *(linea paravertebralis)* – runs vertically along the side of the vertebral column
- 10 **Posterior median line** *(linea mediana posterior)* – runs vertically through the middle of the vertebral column, passing through the spinous processes of the vertebrae

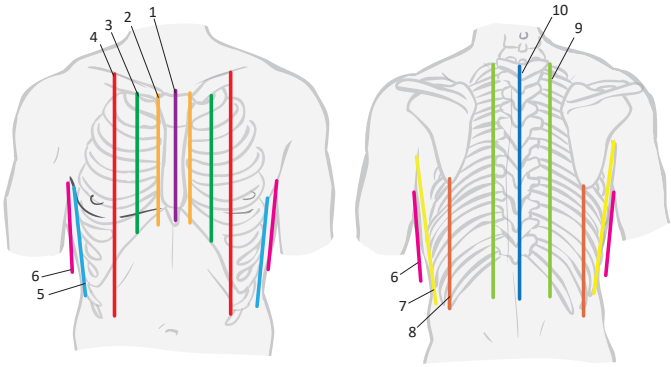

Lines of the human body

Locations and directions are basic orientation descriptions used in both gross and clinical anatomy. They are not only used to describe individual organs but are also used in **topographical anatomy** to decribe the spatial relationships of one organ to another.

Locations and directions used on the whole body

- 1 **Anterior** – towards the front
- 2 **Posterior** – towards the back
- 3 **Superior** – upwards
- 4 **Inferior** – downwards
- 5 **Internal/inner** (*internus*)
- 6 **External/outer** (*externus*)
- 7 **Superficial** *(superficialis)*
- 8 **Deep** *(profundus)*
- 9 **Right** *(dexter)*
- 10 **Left** *(sinister)*
- 11 **Cranial** (*cranialis*) – towards the head
- 12 **Caudal** (*caudalis*)– towards the tail bone
- 13 **Ventral** (*ventralis*) – towards the front
- 14 **Dorsal** (*dorsalis*) – towards the back
- 15 **Medial** *(medialis)* – towards the centre of the body or towards the axis of the limb
- 16 **Lateral** *(lateralis)* – away from the centre of the body or away from the axis of the limb
- 17 **Ipsilateral** – refers to something on the same side of the body
- 18 **Contralateral** – refers to something on the opposite side of the body

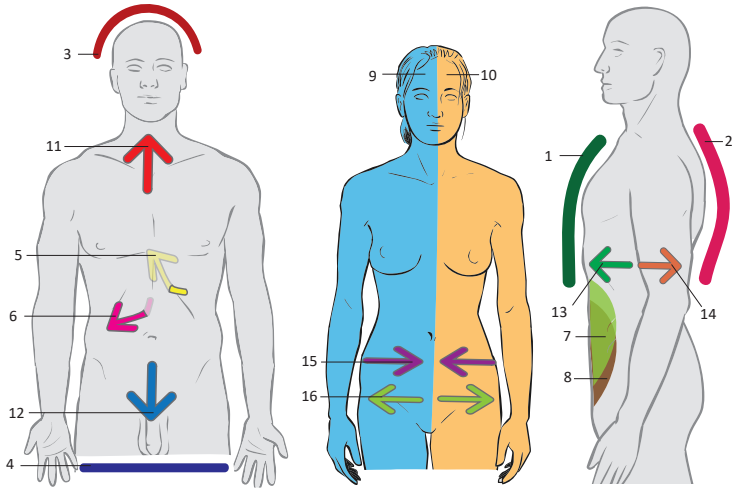

Locations and directions used on the limbs

Directions on the upper and lower limbs:

- 1 **Proximal** (*proximalis*) – towards the trunk
- 2 **Distal** *(distalis)* – away from the trunk
- 3 **Medial** *(medialis)* – towards the middle axis
- 4 **Lateral** *(lateralis)* – away from the middle axis

Directions on the upper limb:

- 5 **Ulnar** *(ulnaris)* – on or towards the ulnar side of the forearm
- 6 **Radial** *(radialis)* – on or towards the radial side of the forearm
- 7 **Palmar**/volar *(palmaris/volaris)* – on or towards the palm
- 8 **Dorsal** *(dorsalis)* – on or towards the dorsum of the hand

Directions on the lower limb:

- 9 **Tibial** *(tibialis)* – on or towards the tibial side of the leg
- 10 **Fibular**/peroneal *(fibularis/peroneus)* – on or towards the fibular side of the leg
- 11 **Plantar** *(plantaris)* – on or towards the sole
- 12 **Dorsal** *(dorsalis)* – on or towards the dorsum of the foot

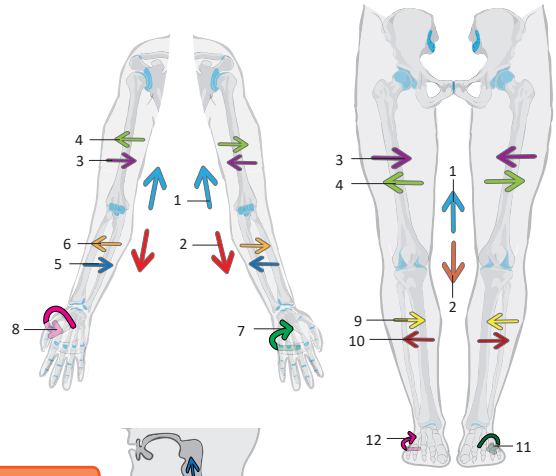

Terms of direction specific for the gastrointestinal tract and the brain

Directions in the gastrointestinal tract:

- 1 **Oral** *(oralis)* – towards the oral cavity
- 2 **Aboral** *(aboralis)* – towards the anal canal

Directions in the brain:

- 3 **Rostral/frontal/cranial** *(rostralis/frontalis/cranialis)* – towards the forehead
- 4 **Caudal/occipital** *(caudalis/occipitalis)* – towards the occiput
- 5 **Dorsal** *(dorsalis)* – towards the cranial vault (calvaria)
- 6 **Ventral/basal** *(ventralis/basalis)* – towards the cranial base

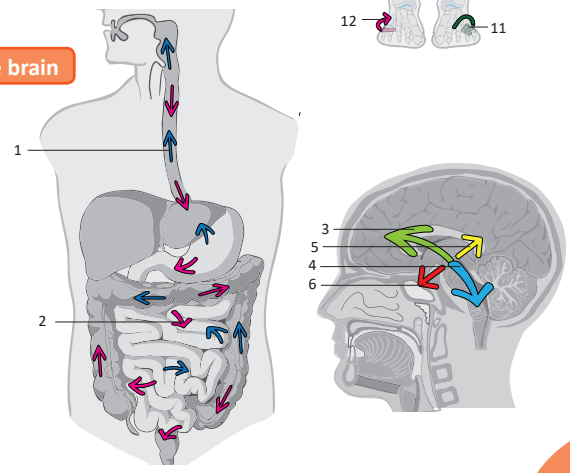

The following terms are used to describe **specific parts of the human body in the standard anatomical position. Constitutional typology** describes body shape according to the height and width of the body, length of the limbs and the amount of muscle and body fat.

Parts of the human body *(partes corporis humani)*

1 **Head** *(caput)*
2 **Neck** *(collum)*
3 **Shoulder** *(omos)*
4 **Axilla, armpit** *(axilla)*
5 **Arm** *(brachium)*
6 **Elbow** *(cubitus)*
7 **Forearm** *(antebrachium)*
8 **Wrist** *(carpus)*
9 **Hand** *(manus)*
10 **Palm** *(palma, vola)*
11 **Thenar eminence** *(thenar / eminentia thenaris)*
12 **Hypothenar eminence** *(hypothenar / eminentia hypothenaris)*
13 **Thumb** *(pollex / digitus primus)*
14 **Index finger** *(index / digitus secundus)*
15 **Middle finger** *(digitus medius/tertius)*
16 **Ring finger** *(digitus anularis/quartus)*
17 **Little finger** *(digitus minimus/quintus)*
18 **Thorax**
19 **Front of chest** *(pectus)*
20 **Abdomen**
21 **Navel** *(umbilicus)*
22 **Pelvis**
23 **Groin** *(inguen)*
24 **Hip** *(coxa)*
25 **Thigh** *(femur)*
26 **Knee** *(genu)*
27 **Leg** *(crus)*
28 **Ankle** *(tarsus)*
29 **Metatarsus**
30 **Foot** *(pes)*
31 **Toes** (*digiti pedis*)
32 **Big toe** *(hallux / digitus primus)*
33 **Nape of neck** *(nucha)*
34 **Upper limb** *(membrum superius)*
35 **Dorsum of hand** *(dorsum manus)*
36 **Fingers** *(digiti manus)*
37 **Back** *(dorsum)*
38 **Loin** *(lumbus)*
39 **Buttocks** *(nates/clunes)*
40 **Lower limb** *(membrum inferius)*
41 **Posterior side of knee** *(poples)*
42 **Calf** *(sura)*
43 **Heel** *(calx)*
44 **Sole** *(planta)*

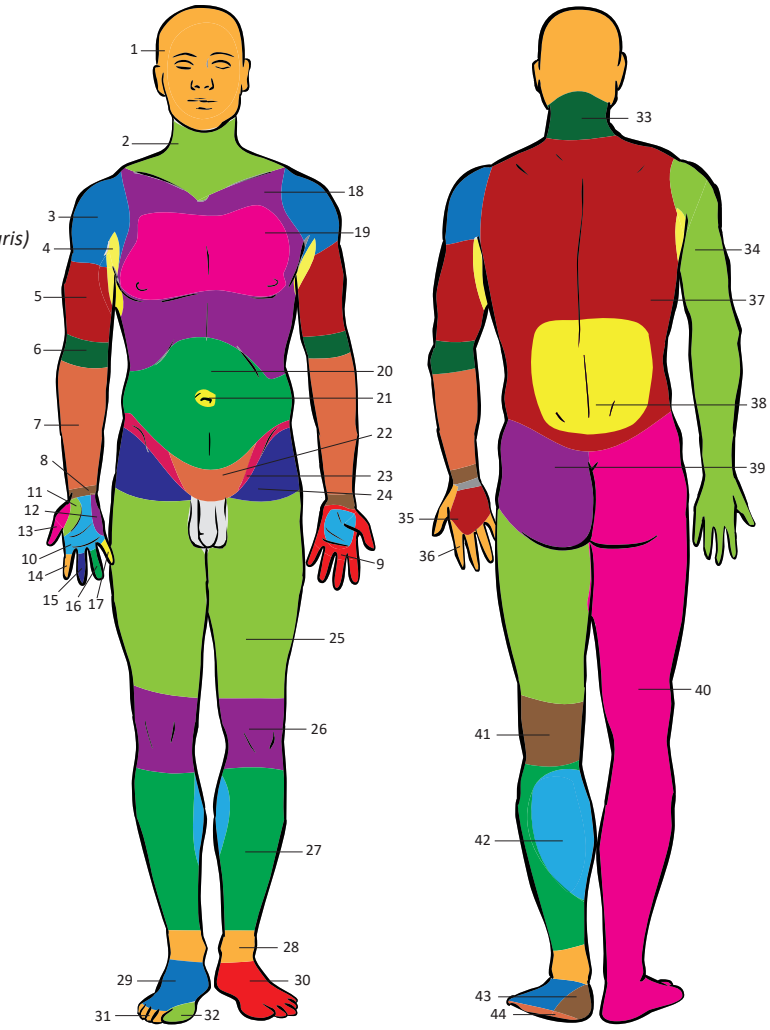

Constitutional typology

Asthenic type / ectomorph
– weak skeleton, poorly developed muscles
– slim trunk, long limbs, small head and oblong shaped face
Athletic type / mesomorph
– strong skeleton, well developed muscles
– long head with flat nose
– prominent bones of the face forming sharp facial features
Pyknic type / endomorph
– fat stocky figure
– round head with a wide straight nose

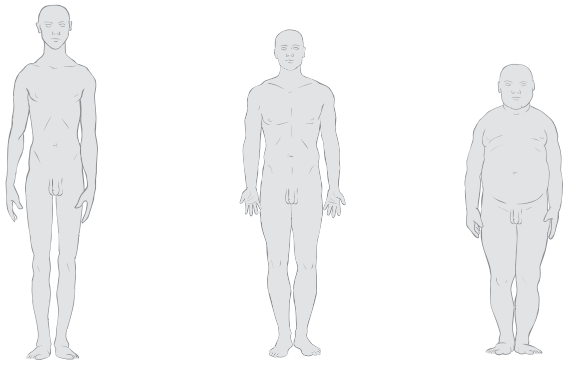

Asthenic type Athletic type Pycnic type

Regions of the human body (*regiones corporis humani*)

Regions of the head (*regiones capitis*):

- 1 **Frontal region** (*regio frontalis*)
- 2 **Parietal region** (*regio parietalis*)
- 3 **Occipital region** (*regio occipitalis*)
- 4 **Temporal region** (*regio temporalis*)
- 5 **Auricular region** (*regio auricularis*)
- 6 **Mastoid region** (*Regio mastoidea*)

Facial regions (*regio facialis*):

- 7 **Orbital region** (*regio orbitalis*)
- 8 **Infra-orbital region** (*regio infraorbitalis*)
- 9 **Buccal region** (*regio buccalis*)
- 10 **Parotid region** (*regio parotideomasseterica*)
- 11 **Zygomatic region** (*regio zygomatica*)
- 12 **Nasal region** (*regio nasalis*)
- 13 **Oral region** (*regio oralis*)
- 14 **Mental region** (*regio mentalis*)

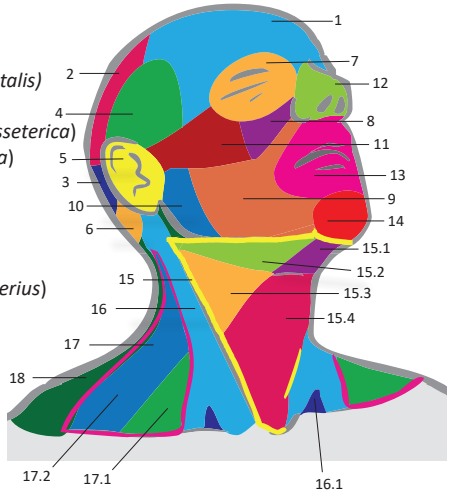

Regions of the head and neck

Regions of the neck (*regiones cervicales*):

- 15 **Anterior cervical region/triangle** (*regio cervicalis anterior* / trigonum *cervicale anterius*)
  - 15.1 **Submental triangle** (*trigonum submentale*)
  - 15.2 **Submandibular triangle** (*trigonum submandibulare*)
  - 15.3 **Carotid triangle** (*trigonum caroticum*)
  - 15.4 **Muscular/omotracheal triangle** (*trigonum musculare/omotracheale*)
- 16 **Sternocleidomastoid region** (*regio sternocleidomastoidea*)
  - 16.1 **Lesser supraclavicular fossa** (*fossa supraclavicularis minor*)
- 17 **Lateral cervical region / posterior triangle of the neck** (*regio cervicalis lateralis / trigonum cervicale laterale*)
  - 17.1 **Omoclavicular triangle / subclavian triangle** (*trigonum omoclaviculare*)
  - 17.2 **Omotrapezoid triangle** (*trigonum omotrapezium*)
- 18 **Posterior cervical region** (*regio cervicalis posterior*)

Thoracic regions (*regiones thoracicae*):

- 1 **Parasternal region** (*regio presternalis*)
- 2 **Clavicopectoral/deltopectoral triangle** (*trigonum clavipectorale/deltopectorale*)
- 3 **Pectoral region** (*regio pectoralis*)
- 4 **Mammary region** (*regio mammaria*)
- 5 **Inframammary region** (*regio inframammaria*)
- 6 **Axillary region** (*regio axillaris*)

Abdominal regions (*regiones abdominales*):

- 7 **Epigastric region** (*regio epigastrica / epigastrium*)
- 8 **Hypochondrium** (*regio hypochondriaca / hypochondrium*)
- 9 **Umbilical region** (*regio umbilicalis / mesogastrium*)
- 10 **Lateral region** (*regio lateralis / mesogastrium*)
- 11 **Pubic region** (*regio pubica / hypogastrium*)
- 12 **Inguinal region** (*regio inguinalis / hypogastrium*)

Regions of the back (*regiones dorsales*):

- 13 **Vertebral region** (*regio vertebralis*)
- 14 **Scapular region** (*regio scapularis*)
- 15 **Infrascapular region** (*regio infrascapularis*)
- 16 **Lumbar region** (*regio lumbalis*)
- 17 **Sacral region** (*regio sacralis*)

Perineal region (*regio perinealis*):

- 18 **Anal triangle** (*regio analis*)
- 19 **Urogenital triangle** (*regio urogenitalis*)

Regions of the upper limb (*regiones membri superioris*):

- 20 **Deltoid region** (*regio deltoidea*)
- 21 **Brachial region** (*regio brachialis*)
- 22 **Cubital region** (*regio cubitalis*)
- 23 **Antebrachial region** (*regio antebrachialis*)
- 24 **Carpal region** (*regio carpalis*)
- 25 **Hand region** (*regio manus*)

Regions of the lower limb (*regiones membri inferioris*):

- 26 **Gluteal region** (*regio glutealis*)
- 27 **Hip region** (*regio coxae*)
- 28 **Femoral region** (*regio femoris*)
- 29 **Knee region** (*regio genus*)
- 30 **Popliteal region** (*regio poplitea*)
- 31 **Leg region** (*regio cruris*)
- 32 **Ankle region** (*regio tarsalis*)
- 33 **Foot region** (*regio pedis*)

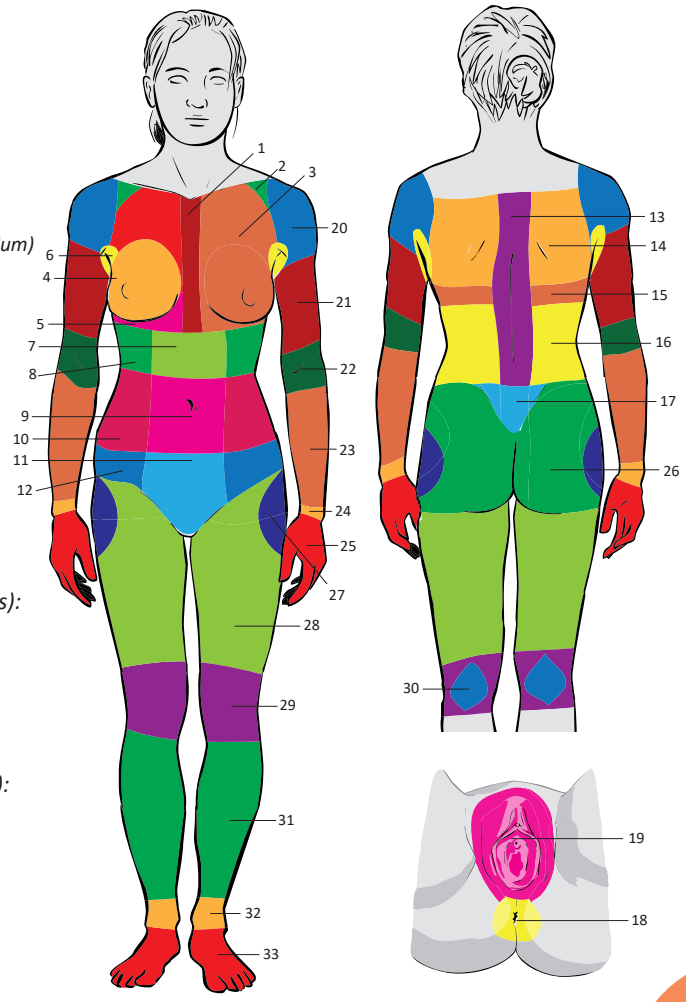

Anatomical terminology uses **eponyms**. Eponyms are terms named after the person that discovered or described the anatomical structure. Their use lies **predominantly in clinical anatomy.**

1. **ACHILLES** **Achilles' tendon** – the tendon of the triceps surae, named after a Greek mythological warrior
2. **ALCOCK** **Alcock's canal** – a space on the inner side of the obturator internus
3. **ARANTIUS** **Arantius' duct** – a shunt found in the foetus that allows blood to pass from the umbilical vein to the inferior vena cava, bypassing the liver
4. **ASCHOFF** **Aschoff-Tawara's node** – the AV node of the conducting system of the heart
5. **AUERBACH** **Auerbach's myenteric plexus** – a nervous plexus within the muscular layer of the gastrointestinal tract
6. **BARTHOLINUS** **Bartholin's glands** – mucous glands in the vestibule of the vagina
   Bartholin's duct – the largest excretory duct of the sublingual salivary gland
7. **BAUHIN** **Bauhin's valve** – a narrowing at the transition between the small and large intestines
8. **BILLROTH** **Cords of Billroth** – the red pulp cords between sinusoids in the spleen
9. **BOCHDALEK** **Bochdalek's triangle** – a triangular defect between the lumbar and costal parts of the diaphragm
   Bochdalek' flower spray – a protrusion of the choroid plexus of the fourth ventricle through the lateral aperture into the subarachnoid space
10. **BÖHME** **Cannon-Böhm point** – a point located between the middle and left thirds of the transverse colon that marks the transition of parasympathetic innervation from the vagus nerve to the sacral splanchnic nerves
11. **BOTALLO** **Ductus Botalli** – a foetal shunt connecting the pulmonary trunk to the aortic arch
12. **BOWMAN** **Bowman's capsule** – a sac, enclosing the glomerulus, forming the first part of the nephron
13. **BROCA** **Broca's area** – an area of cortex located in the posterior part of the inferior frontal gyrus in the speech dominant hemisphere (Brodman areas 44 and 45)
14. **BRODMANN** **Brodman's map** – a cytoarchitectural map of the cerebral cortex
15. **CAJAL** **Cajal's nucleus** – a group of neurons located in the periaqueductal grey substance of the tegmentum of the midbrain
16. **CALOT** **Calot's triangle** – an anatomical space containing a potential ligation site of the cystic atery
17. **CAMPER** **Fascia of Camper** – a fibrous-adipose layer of the anterior abdominal wall
18. **CHOPART** **Chopart's joint** – a joint line located transversely through the tarsal bones
19. **CLARKE** **Stilling-Clarke's nucleus** – a nucleus located in the posterior horn of the spinal cord
20. **CLAUDIUS** **Claudius' fossa** – a slight depression that houses the ovary, located between the internal iliac vessels and the sacrum
21. **CLOQUET** **Cloquet's node** – the most proximal of the deep inguinal lymph nodes, located in the lacuna vasorum
22. **COCKETT** **Cockett's** perforators – three connections between the superficial and deep venous system, located on the medial side of the calf
23. **CORTI** **Organ of Corti** – the auditory organ proper
24. **DOUGLAS** **Pouch of Douglas**– the deepest space of the peritoneal cavity in women
25. **EUSTACHIO** **Eustachian tube** – the auditory tube, a connection between the nasopharynx and tympanic cavity,
    Eustachian valve – the valve of the inferior vena cava, located in the right atrium of the heart
26. **FALLOPPIO** **Fallopian canal** – the part of the facial canal located in the petrous part of the temporal bone
    Fallopian tube – the uterine tube
27. **FLACK** **Keith-Flack's node** – the SA node of the conducting system of the heart
28. **FROHSE** **Frohse's arcade** – a fibrous arch in the supinator canal
29. **GALENOS** **Vein of Galen** – the largest cerebral vein, drains blood from the deep parts of the brain into the straight sinus
30. **GASSER** **Gasser's ganglion** – the sensory ganglion of the trigeminal nerve
31. **GEROTA** **Gerota's fascia** – covers the perinephric fat capsule
32. **GOLGI** **Golgi complex** – a cellular organelle
    Golgi tendon organ – a proprioceptor found in tendons
33. **GRAAF** **Graafian follicle** – the mature ovarian follicle
34. **GUYON** **Guyon's canal** – a space on the wrist through which the ulnar neurovascular bundle enters the hand
35. **HALLER** **Tripus Halleri** – the coeliac trunk, a branch of the aorta that trifurcates into three visceral branches
    Haller's anastomosis – an arterial connection between the branches of the superior and inferior mesenteric artery
36. **HAVERS** **Haversian system** – the osteon, a complex of concentric lamellae of bone surrounding the Haversian canal
    Haversian canal – the canal of the osteon, contains vessels, nerves and loose connective tissue
37. **HENLE** **Loop of Henle** – a loop in the nephron between the proximal and distal tubules
38. **HESSELBACH** **Hesselbach's triangle** – a weakening in the anterior abdominal wall where direct abdominal hernias occur
    Corona mortis of Hesselbach – an aberrant obturator artery crossing the linea terminalis and passing into the lesser pelvis
39. **HIGHMORE** **Antrum of Highmore** – the maxiliary sinus, an air-filled cavity in the maxillary bone
40. **HIS** **Bundle of His** – a part of the conducting system of the heart
41. **HUNTER** **Hunter's canal** – the adductor canal, a space on the medial side of the thigh through which the femoral vessels pass
42. **HYRTL** **Hyrtl's canal** – a space containing the fibular vessels, located between the flexor hallucis longus, interosseous membrane and fibula
43. **KEITH** **Keith-Flack node** – the SA node of the conducting system of the heart
44. **KIESSELBACH** **Kiesselbach's plexus** – a vascular plexus located in the nasal septum with a high propensity to bleed
45. **KILLIAN** **Killian's triangle** – a narrowing at the transition between the pharynx and oesophagus

46. KOHLRAUSCH **Kohlrauch's fold** – the right transverse fold of the rectum
47. LANGERHANS **Islets of Langerhans** – the hormone-producing part of the pancreas
48. LIEBERKÜHN **Crypts of Lieberkühn** – glands of the small intestine
49. LISFRANC **Lisfranc's joint** – an articular line located transversely through the metatarsal bones
50. LUSCHKA **Foramina of Luschka** – paired lateral openings draining cerebrospinal fluid from the fourth ventricle into the subarachnoid space
51. LUYS **Luys' body** – the subthalamicus nucleus of the diencephalon
52. MAGENDIE **Foramen of Magendie** – an unpaired median opening draining cerebrospinal fluid from the fourth ventricle into the subarachnoid space
53. MALPHIGI **Renal corpuscle of Malphigi** – the initial part of the nephron
54. McBURNEY **McBurney's point** – the projection of the appendix on the surface of the anterior abdominal wall
55. MECKEL **Meckel's cavity** – a cavity within the dura mater housing the trigeminal ganglion
56. MECKEL **Meckel's diverticle** – a blind variable developmental pouch located on the ventral side of the ileum
57. MEIBOM **Meibomian glands** – apocrine glands of the eyelid
58. MEISSNER **Meissner's plexus** – a nervous plexus in the submucosa of the gastrointestinal tract
Meissner's corpuscles – tactile receptors located in the dermis
59. MONRO **Foramina of Monro** – paired apertures connecting the lateral and third ventricles
Monro line – a line connecting the navel and right superior anterior iliac spine
60. MÜLLER **Müllerian duct** – the embryonic precursor of the female genital tract
61. ODDI **Sphincter of Oddi** – the sphincter of the bile duct
62. PAWLIK **Pawlik's triangle** (*area trigonalis vaginae*) – a triangular space where the anterior wall of vagina and the trigone of the urinary bladder are in contact
63. PEYER **Peyer's patches** – lymphoid nodules aggregated in the submucosa of the ileum
64. POUPART **Poupart's ligament** – the inguinal ligament
65. PURKYNĚ **Purkynje's (Purkyně's) fibers** – terminal branches of the conducting system of the heart located beneath the endocardium in the ventricles
Purkynje's (Purkyně's) cells – large efferent neurons within the Purkinje cell layer *(stratum purkinjese)* of the cerebellar cortex
66. RANVIER **Nodes of Ranvier** – gaps in the myelin sheath of neurons between Schwann's cells
67. RATHKE **Rathke's pouch** – a pouch in the upper part of the stomodeum that gives rise to the adenohypophysis
68. RETZIUS **Veins of Retzius** – retroperitoneal venous connections between the portal and caval venous systems
Retzius' space – a space between the pubic symphysis and the urinary bladder
69. REXED **Rexed laminae** – 10 layers of grey matter on the transverse section of the spinal cord
70. ROLANDO **Rolando's substance** – a nucleus located in the posterior horn of the spinal cord
Rolandic sulcus – the central sulcus of the cerebral cortex
71. SANTORINI **Santorini's papilla** – the opening of the accessory pancreatic duct into the duodenum
72. SCARPA **Fascia of Scarpa** – a subcutaneous fibrous layer of the anterior abdominal wall
73. SCHLEMM **Schlemm's canal** – a channel that drains aqueous humor into the bloodstream
74. SCHWANN **Schwann cells** – cells covering the axons in the peripheral nervous system
Schwann's sheath – the neurolemma, the outer layer of the Schwann cell
75. SORGIUS **Sorgius node** – the sentinel lymph node of spreading breast tumours, located on the second or third slip of the serratus anterior
76. STENSEN **Stensen duct** – the excretory duct of the parotid gland
77. SYLVIUS **Aqueduct of sylvius** – connects the third and fourth ventricles in the brainstem
Sylvian fissure – divides the frontal and parietal lobes from the temporal lobe
78. TAWARA **Tawara's branches** – right and left branches of the atrioventricular bundle in the conducting system of the heart
79. TREITZ **Muscle/ligament of Treitz** – the suspensory muscle (or ligament) of the duodenum extending from the right crus of the diaphragm to the duodenojejunal flexure
Treitz's retropancreatic membrane – the fibrous remnant of the dorsal mesoduodenum separating the pancreas from the great retroperitonal vessels
Treitz's intersigmoid recess – a peritoneal recess between the parietal peritoneum and the sigmoid mesocolon
80. VATER **Ampulla of Vater** – the common opening of the pancreatic duct and the bile duct in the duodenum
Vater-Pacinian corpuscles – tactile receptors in the skin
81. VIRCHOW **Virchow-Robin spaces** – pouches of the subarachnoid space located around vessels under the pia mater
Virchow-Troisier lymph nodes – the left supraclavicular lymph nodes
82. WALDEYER **Waldeyer's ring** – a group of tonsils arranged in a ring in the pharynx
83. WERNICKE **Wernicke's area** – an area of the cerebral cortex located in the superior temporal gyrus (Brodmann area 22) in the dominant hemisphere
84. WHARTON **Wharton's duct** – the excretory duct of the submandibular gland
Wharton's jelly – connective tissue in the umbilical cord
85. WILLIS **Circle of Willis** – a circular arterial anastomosis located at the base of the brain

I. Definitions and history

1. Explain the difference between anatomical terminology and nomenclature. (p. 2)
2. Explain the phrase “obsolete term”. (p. 2)
3. Explain what an eponym is. (p. 2)
4. Explain the difference between systematic and topographic anatomy. (p. 2)
5. State the author, year and name of the publication of the first modern textbook of anatomy. (p. 2)

II. Terms and abbreviations

6. List all the different structures termed “sinus”. (p. 3)
7. Explain the difference between the abbreviations “gl.” and “gll.”. (p. 3)
8. Define the abbreviations “l.sin.” and “l.dx.”. (p. 3)
9. Give the abbreviations of the terms “superior” and “inferior”. (p. 3)

III. Histology

10. Describe the function of the smooth and granular endoplasmic reticulum. (p. 4)
11. List all the components of the cytokeleton. (p. 4)
12. Name all the different types of epithelium and state where each type can be found. (p. 4)
13. Name three types of cartilage and describe where they can be found. (p. 4)
14. Name three types of muscle tissue and describe where they can be found. (p. 4)

IV. Embryology

15. Explain the term “primary germ layers”. (p. 5)
16. Name the parts of the human body that originate from the endoderm. (p. 5)
17. List all the places to which the cells of the neural crest migrate. (p. 5)
18. State which muscles have a branchiogenic origin. (p. 5)
19. State which cranial nerves innervate which muscles. (p. 5)
20. Define the embryogenic period. (p. 5)
21. Name the three primary germ layers and some structures that originate from them. (p. 5)
22. List the muscles that originate from each pharyngeal arch. (p. 5)

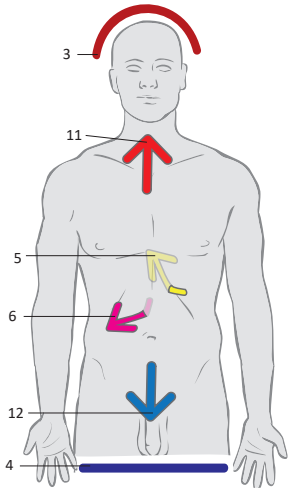

Describe the anatomical terminology for directions and locations

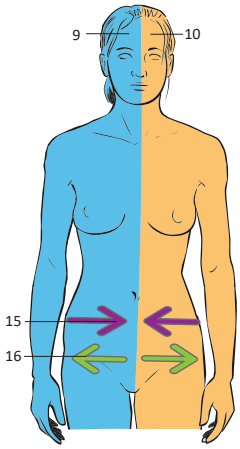

Describe the anatomical terminology for directions and locations

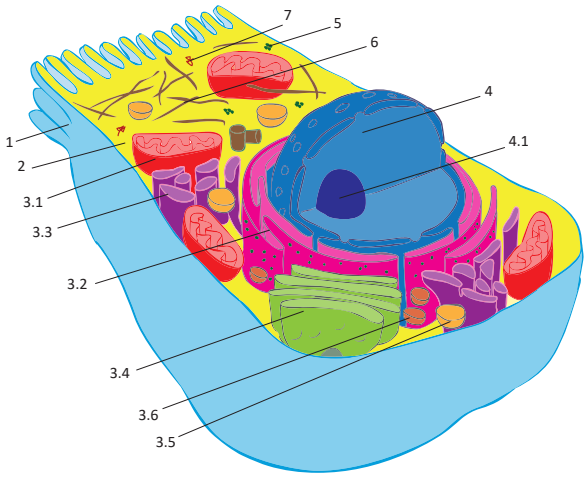

Name and describe the components of the eukaryotic cell

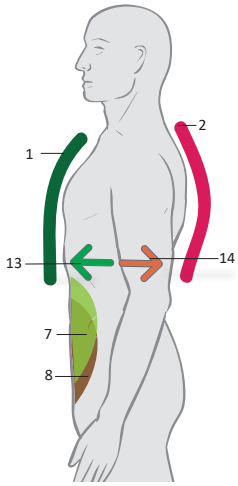

Describe the anatomical terminology for directions and locations

V. Anatomical changes in childhood

23. Define the term “menarche”. (p. 6)
24. State to which level the spinal cord extends in an adult and explain why. (p. 6)
25. State the weight of the brain of a newborn and an adult. (p. 6)
26. State all the organs that change location during development and explain why they do this. (p. 6)
27. Describe the changes of the ratio of the size of the head and trunk during development. (p. 6)

VI. Anatomical changes in puberty

28. Explain what is the Tanner scale. (p. 7)
29. Describe the shape changes of the breast in females. (p. 7)
30. List the different stages of development of the male external genital organs (p. 7)

VII. Planes and lines of the human body

31. Describe in detail the basic anatomical position. (p. 8)
32. Define the median plane. (p. 8)
33. State and define which lines go through the lateral side of the thorax. (p. 8)

VIII. Terms of direction and location

34. Define the term “contralateral”. (p. 9)
35. Explain the differences in terminology of direction on the trunk, limbs and brain. (p. 9)
36. List the terms of direction and location used on the upper limb. (p. 9)
37. Define the term “aboral”. (p. 9)

IX. Parts of the human body and constitutional typology

38. State the Latin term for the thumb and big toe. (p. 10)
39. Descibe the asthenic body type. (p. 10)

X. Regions of the human body

40. List the four regions of the neck and list the triangles that can be found in each region (p. 11)
41. List the six regions of the abdomen. (p. 11)

XI. Eponyms

42. List two structures named after J. E. Purkyně. (p. 12)
43. List the embryonal vascular ducts and explain their function. (p. 12–13)
44. List all lymph nodes that have eponyms. (p. 12–13)
45. State all parts of the body associated with the eponym “Treitz”. (p. 12)

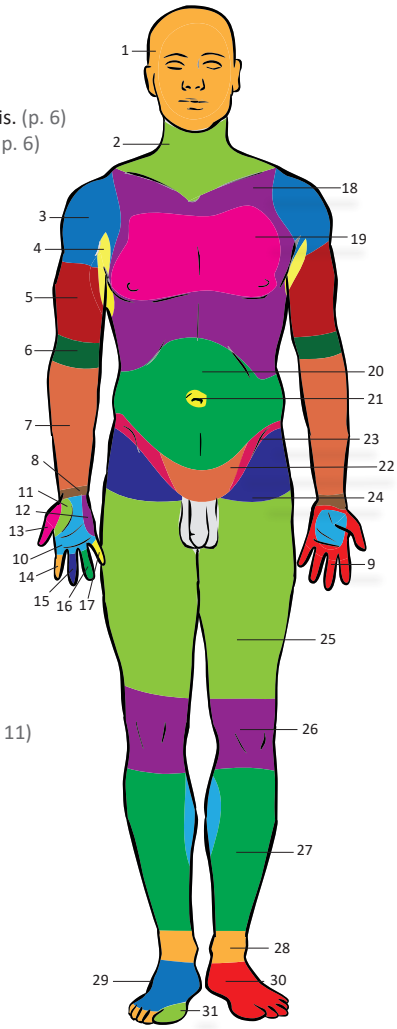

Describe the main regions of the human body

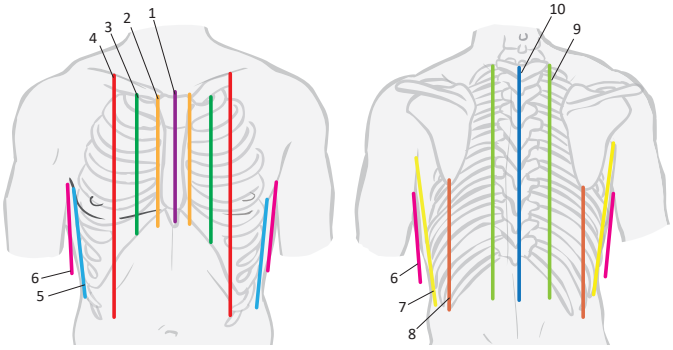

Describe the anatomical lines of the human body

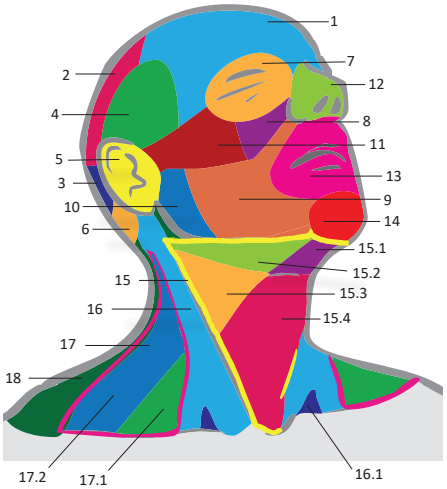

Describe the regions of the head and neck

We would like to **thank the following anatomists and medical students** for their endless help, devotion and feedback in the preparation of this chapter.

Anatomists

Assoc. prof. Václav Báča, MD, PhD – Department of Anatomy, Third Faculty of Medicine, Prague, Czech Republic
Emer. Prof. Stephen Carmichael, PhD, DSc. – Mayo Clinic, Rochester, USA

Medical students

Lucie Olivová
Rachel White
Klára Macháčková

13 References

1. ABRAHAMS, P. H.; SPRATT, J. D.; LOUKAS, M. and A. N. van SCHOOR. McMinn and Abrahams' Clinical Atlas of Human Anatomy: with Student Consult Online Access (Mcminn's Color Atlas of Human Anatomy). 7th Ed. Philadelphia: Mosby Elsevier, 2013, 388 p. ISBN 978-0723-43697-3.
2. AGUR, A. M. R. and A. F. DALLEY. Grant's Atlas of Anatomy. 13th Ed. Philadelphia: Lippincot Williams & Wilkins, 2012, 888 p. ISBN 978-1-60831-756-1.
3. FCAT. Terminologia anatomica: international anatomical terminology. Stuttgart: Thieme Verlag, 1998, 300 p. ISBN 978-3-13-114361-4.
4. CHUNG, K. W.; CHUNG, H. M. and N. L. HALLIDAY. BRS Gross Anatomy. 8th Ed. Philadelphia: Lippincott Williams & Wilkins, 2015. 544 p. ISBN 978-1-4511-9307-7.
5. LANZ, T. and W. WACHSMUTH. Praktische Anatomie. 7 bands. Berlin: Springer, 2003, 3658 p. ISBN 978-3-540-40571-9.
6. MOORE, K. L.; DALLEY, A. F. and A. AGUR. Clinically oriented anatomy. 7th Ed. Philadelphia: Lippincot Williams & Wilkins, 2014. 1139 p. ISBN 978-1-4511-1945-3.
7. NETTER, F. H. Atlas of Human Anatomy. Professional Edition. 6th Ed. Oxford: Elsevier. 2014. 640 p. ISBN 978-1-455-75888-3.
8. ROHEN, J. W. LUTJEN-DRECOLL, E. and C. YOKOCHI. Color Atlas of Anatomy: A Photographic Study of the Human Body. 7th Ed. Stuttgart: Lippincot Williams & Wilkins, 532 p. ISBN 978-1-58255-856-1.
9. WILLIAMS, P. L., ed. Gray´s Anatomy: the anatomical basis of medicine and surgery. 38th Ed. New York: Churchill Livingstone, 1995, 2092 p. ISBN 0-443-05717-6.

Be an Anatomist at heart!

Book contents:

This sample contains a free chapter
1. General anatomy.
You will find it below the introduction of the book.
You can buy the whole ebook at our website.